

*A short note on heavy infection
of acanthocephalan worm
(*Neoechinorhynchus agilis*) in grey mullet,
*Mugil cephalus**

Journal of Parasitic Diseases


ISSN 0971-7196

Volume 34

Number 2

J Parasit Dis (2011) 34:99-101

DOI 10.1007/s12639-010-0019-
y



Your article is protected by copyright and all rights are held exclusively by Indian Society for Parasitology. This e-offprint is for personal use only and shall not be self-archived in electronic repositories. If you wish to self-archive your work, please use the accepted author's version for posting to your own website or your institution's repository. You may further deposit the accepted author's version on a funder's repository at a funder's request, provided it is not made publicly available until 12 months after publication.

A short note on heavy infection of acanthocephalan worm (*Neoechinorhynchus agilis*) in grey mullet, *Mugil cephalus*

K. P. Jithendran · S. Kannappan

Received: 29 June 2010 / Accepted: 28 December 2010 / Published online: 11 January 2011
© Indian Society for Parasitology 2011

Abstract Infection with acanthocephalan parasite, *Neoechinorhynchus agilis* (Acanthocephala: Neoechinorhynchidae) is reported from adult mullet (*Mugil cephalus*). Heavy infections with the parasites were observed in the posterior region of the intestine, almost blocking the lumen. At the site of parasite attachment, the surface of the intestine appeared thickened and the mucosal epithelium. A description of the parasites and its clinicopathology is discussed.

Keywords Acanthocephalans · Spiny headed worm · *Neoechinorhynchus agilis* · Infection · *Mugil cephalus*

Introduction

Parasitic diseases pose great problem in the culture and captive maintenance of brackishwater fishes. Among them, acanthocephalans are ‘thorny’ or ‘spiny headed’ worms with aquatic life cycles; fish as final or paratenic hosts and crustaceans as intermediate hosts (Mehlhorn 1988). Adults feed on the intestinal walls of vertebrates, especially freshwater and marine fishes. They are often encountered in culture system as majority of the brood stock fishes are sourced from wild. Worms are dioecious endoparasites; males usually smaller than females. In the course of our routine investigation on parasitic diseases of finfish, a case of heavy infection of ‘thorny headed worm’ was observed in a wild catch of mullet fish. The present study describes

the morphology, taxonomy and clinicopathology of infection.

Materials and methods

Fish samples of grey mullet (*Mugil cephalus*) weighing 557–810 g from a collection of fish from landing centre near Chennai (Tamil Nadu) were examined in the laboratory for parasitic infections. Wet mounts of scrapings from the skin, fins and gills were prepared and examined under microscope for ectoparasites. Similarly, the gills and visceral organs were also dissected out and examined under stereozoom microscope for any internal parasites. The parasites were examined live and morphological details were recorded for taxonomic identification. A representative number of worm viz., acanthocephalans recovered was first washed in saline solution, placed in distilled water in cold to force osmotic evagination of the proboscis. Subsequently, the worms were fixed in alcohol/formalin/acetic acid (AFA) fixative and preserved in 70% ethanol until processed for identification. The worms were cleared in clove oil and examined under microscope for internal details. For histological studies, the visceral organs were fixed in neutral buffered formalin and processed for paraffin wax sections. Sections (4–5 µm) were stained using haematoxylin and eosin and examined. Photomicrographs were taken using an Olympus digital camera C7070 fitted to Olympus CX41 microscope.

Results and discussion

The gross examination of the mullet intestine revealed ivory coloured, unsegmented (but with marked pseudo

K. P. Jithendran (✉) · S. Kannappan
Central Institute of Brackishwater Aquaculture, 75 Santhome
High Road, R. A. Puram, Chennai 600 028, India
e-mail: kpjithendran@yahoo.com

segmentation of the cuticle), cylindrical sac like worms, measuring 1.8–3.2 cm in length and an anterior retractile proboscis with hooks. Male were smaller than females. The worms were found to be in packed condition in the lumen of the intestine, majority of them attached to intestinal mucosa (Fig. 1a) while some in the peritoneal cavity. No other visible abnormalities were observed in any of the internal organs except the thickening of intestinal wall at the site of attachment. The taxonomy of the worms were attempted by clearing the specimens in clove oil and identified as acanthocephalan parasite. On microscopic examination the metasoma of the parasite was cylindrical, relatively short proboscis was as long as wide, armed with a set of hooks arranged in three circles of six hooks, first rows of hooks largest. The neck was not clearly demarcated (Fig. 1b, c). The elongate oval testes lie one behind the other in the middle third of the body. Female worms revealed large number of ovarian balls inside in the ligament sac. The spindle-shaped eggs measures up to $42 \times 12 \mu\text{m}$ and contain embryo. The morphological characteristics of the specimens, shape and size of proboscis, the low number and position of the spines on the proboscis clearly place this species within the genus *Neoechinorhynchus* and conform to the descriptions for *Neoechinorhynchus agilis* Rudolphi, 1819 belonging to Acanthocephala: Neoechinorhynchidae (Yamaguti 1935).

This study documents the occurrence of heavy infection (26–68 number/fish) of acanthocephalan parasite, *Neoechinorhynchus* in marine fish *Mugil cephalus*. The acanthocephalan genus *Neoechinorhynchus* is a relatively large genus with approximately 70–75 species and typically found in freshwater fishes (Ching 1984). The biodiversity of acanthocephalan species in fish is largely unknown in India. There are some reports of the genus *Neoechinorhynchus* from Indian marine fishes (Tripathi 1959; Chandra et al. 1985) besides other acanthocephalan species, *Serrasentis nadakali* from *Rachycentron canadum* (George and Nadakal 1981) and *Tenuiproboscis* sp. in many marine fish species with aquaculture potential (Sanil et al. 2011). The fishes were apparently healthy except choking of intestinal tract with several live acanthocephalan worms. Histology of the internal organs showed normal tissue architecture and there was no indication of disease except intestinal sections showing massive epithelial sloughing and haemorrhages due to piercing of tissues with the hooks.

This study contributes to the knowledge of the acanthocephalans in wild brackishwater/marine fish in general as well as to the *Neoechinorhynchus* sp. in particular. *Neoechinorhynchus agilis* has been recorded in a study on grey mullets from Aegean Sea (Altunel 1983). This is a typical parasite of mugilids in the Mediterranean and Far-Eastern waters. Generally, co-infection with

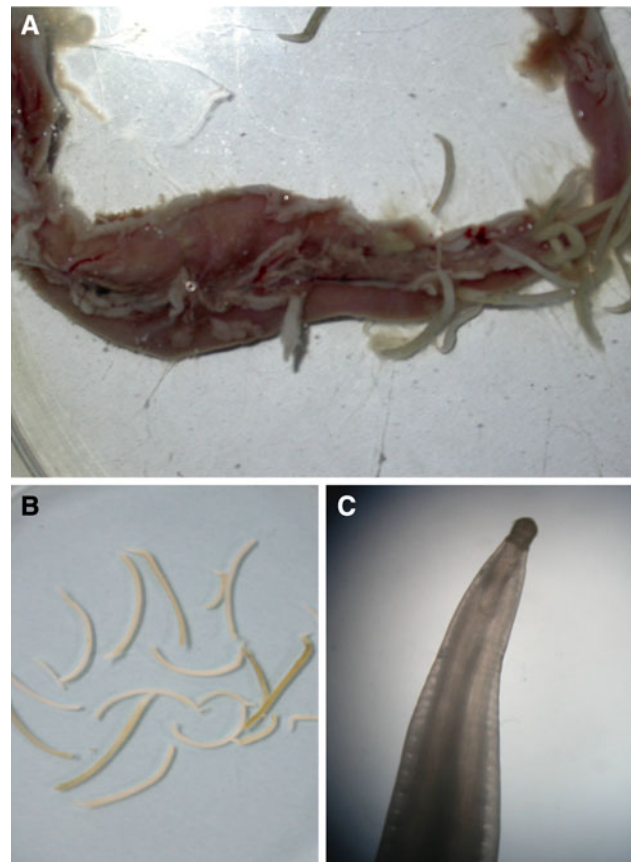


Fig. 1 Intestinal tract of the Mullet (*Mugil cephalus*) showing heavy infection of acanthocephalan parasite (a), gross morphology (b), and microscopic view of the anterior end showing proboscis and pseudosegmentation (c) $40\times$

nematode parasites has been observed, but the present case showed mono-infection with acanthocephalans alone in the intestinal tract. Histopathological changes in fish intestines due to acanthocephalan infections depend on various factors such as species of parasite and host nature of the infected tissues and host-parasite interactions. Usually in acanthocephalan infections, pathology appears to be negligible when parasites are attached to the epithelial mucosa only. Kabata (1985) opined that the number of worms present is important in determining the severity of damage. In heavily infected fish acanthocephalans may perforate the gut wall with their proboscis and cause considerable damage with severe local inflammatory reaction. Further, the number of acanthocephalans per fish seemed to increase with the size of the host fish. A similar finding has been reported by various workers in case of other species of acanthocephalans as well. Though, currently the hatchery production of finfishes in the region depends solely on brood stock sourced from the wild, the importance of acanthocephalans to aquaculture was never high enough to prompt development of specific control measures. Pond reared or wild caught fish with access to the crustacean

intermediate hosts may be infected. Hence, maintenance of water quality and pre-stock management to check the entry of infective stages and their multiplication in the rearing system through crustacean intermediate hosts is of paramount importance.

Acknowledgments The authors are grateful to Dr. Kazuya Nagasawa, Graduate School of Biosciences, Hiroshima University (Japan) for taxonomic identification of the parasite studied in this paper.

References

- Altunel FN (1983) Parasites of mugilid fishes, *Mugil cephalus*. J Ser B 364–378 (in Turkish)
- Chandra KJ, Hanumantha Rao K, Shyamasundari K (1985) On *Neoechinorhynchus argentanus* n. sp., an acanthocephalan parasite from a marine fish of Waltair. Rivista di Parassitologia 45:49–52
- Ching HL (1984) Description of *Neoechinorhynchus salmonis* sp. n. (Acanthocephala: Neoechinorhynchidae) from fresh water fishes of British Columbia. J Parasitol 70:286–291
- George PV, Nadakal AM (1981) Observations on the intestinal pathology of the marine fish, *Rachycentron canadus* (Gunther) infected with the acanthocephalid worm *Serrasentis nadakali* (George & Nadakal 1978). Hydrobiologia 78:59–62
- Kabata Z (1985) Parasites and diseases of fish cultured in the tropics, 1st edn. Taylor & Francis, London, p 318
- Mehlhorn H (1988) Parasitology in focus: facts and trends. Springer Verlag, Berlin, p 924
- Sanil NK, Asokan PK, John L, Vijayan KK (2011) Pathological manifestations of the acanthocephalan parasite, *Tenuiproboscis* sp. in the mangrove red snapper (*Lutjanus argentimaculatus*) (Forsskål 1775), a candidate species for aquaculture from Southern India. Aquaculture 310:259–266
- Tripathi YR (1959) Studies on parasites of Indian fishes. 5 Acanthocephala. Rec Indian Mus 54(1–2):61–99
- Yamaguti S (1935) Studies on the helminth fauna of Japan Part 8 Acanthocephala, I. Jpn J Zool 6:247–278