



CLINICO-PATHOLOGICAL FEATURES AND MANAGEMENT OF AN OUTBREAK OF CONTAGIOUS ECTHYMA IN AN ORGANIZED GOAT FARM IN RAJASTHAN

G.G. Sonawane*, B.N. Tripathi², Riyesh, T², S. Barua², F. Singh, Vinodh Kumar¹, S.K. Dixit, J. Kumar and R.K. Singh¹

ICAR - Central Sheep and Wool Research Institute, Avikanagar- 304 501, Rajasthan

¹ICAR - Indian Veterinary Research Institute, Izatnagar- 243 122, Uttar Pradesh

²Veterinary Type Culture Collection, ICAR - National Research Centre on Equines, Hisar- 125 001, Haryana

*E-mail address: sganesh413@yahoo.com

Manuscript received on 14.10.2014, accepted on 20.11.2014

DOI: 10.5958/0973-9718.2015.00046.X

ABSTRACT

An outbreak of contagious ecthyma was investigated in an organized goat farm in village Tyod in Jaipur district of Rajasthan. The outbreak occurred during the first week of June, 2012 in Beetal goats purchased from Punjab. Within a week, all the goats (24 females and 1 male) were affected with skin lesions accompanied by anorexia and fever. On the basis of clinical symptoms and the extent of gross lesions, animals were categorized into three groups viz., phase I, II and III. Of the 25 Beetal goats, four females and one male showed initial lesions (Phase I) such as papules and pustules at the oral commissures and muzzle. Twelve goats showed moderate lesions (Phase II) of ecthyma. Eight goats were highly emaciated and exhibited anorexia, pyrexia and severe lesions (Phase III) at the oral commissures, muzzle and nostrils as well as haemorrhagic ulcers in buccal mucosa. With the passage of time, the infection spread to other goat flocks of Jakhrana and non-descript goats in which two females of each breed exhibited phase II lesions. Of the 20 kids, only one male kid of Beetal goat was found affected with anorexia, fever and phase I lesions of the disease. The presence of contagious ecthyma in the affected goats was confirmed by specific polymerase chain reaction. Jamunapari, Sirohi, Totapari goats and bucks kept for commercial purposes at the premises did not reveal any clinical signs of the disease. Categorization of the affected animals made it easy to offer an effective treatment as well as prevention of spread of infection in non-affected goats.

Key words: Clinical management, Contagious ecthyma, Goats, Morbidity, Rajasthan

Contagious ecthyma is an acute, contagious, debilitating and economically important zoonotic viral disease of sheep, goats and some other domesticated and wild ruminants (Mondal et al., 2006). The disease is caused by orf virus (ORFV), a member of the genus *Parapoxvirus* in the family *Poxviridae*. The disease is known by a variety of names including sore mouth, contagious pustular dermatitis or scabby mouth (Thomas et al., 2003). The disease is usually more severe in goats than in sheep. In the last several years, many ORFV outbreaks have been reported worldwide including India (Mondal et al., 2006; Ramesh et al., 2008; Abrahao et al., 2009; Venkatesan et al., 2011). ORFV is an epitheliotropic

virus that generally causes proliferative lesions characterized by maculopapular, vesicular pustules that mainly affect the skin around the lips, mouth muzzle, nostrils, teats, and oral mucosa and rarely extends into the oesophagus, stomach, intestine, or the respiratory tract of sheep, goats and wild animals. The mortality rate related to this disease is usually low but it can reach up to 93% in lambs with secondary fungal and bacterial infections (Zhao et al., 2010). Diagnosis of contagious ecthyma can be done on the basis of characteristic lesions and can be confirmed by electron microscopy, polymerase chain reaction (PCR), histopathology and virus isolation (Wilson et al., 2002; Zheng et al., 2007). Vaccination is practiced

in some areas but the duration of immunity after vaccination is controversial. In most cases, animals that have been vaccinated with ORFV are immune for life (Bath et al., 2005). However, outbreaks of orf have also been reported in orf-vaccinated animals (Pye, 1990) indicating that continuous re-infection with ORFV is possible. The present communication reports investigation and successful management of an outbreak of contagious ecthyma in an organized goat farm in semi-arid Rajasthan.

MATERIALS AND METHODS

An organized goat farm in village Tyod of Jaipur district in semi-arid Rajasthan maintained different breeds of goats (Jakhrana, Jamunapari, Beetal, Sirohi, Totapari and non-descript) for breeding purposes. A group of 24 bucks were also maintained for commercial purposes under *optimum* feeding. The clinical symptoms of the disease appeared in the first week of June 2012 in Beetal goats brought from Punjab in May, 2012. On the basis of clinical symptoms and the extent of gross lesions, animals were categorized into three groups viz., phase I, II and III. In phase I, lesions consisted of papules and pustules at the oral commissures and on the muzzle. The moderate lesions (phase II) were observed as scabs at the oral commissures and discrete areas of scab formation with pustules on the muzzle. Phase III animals were highly emaciated and showed anorexia and pyrexia (105-106°F). Severe lesions were observed at the oral commissures consisting of thick and firm scabs covering raised areas of ulceration and granulation with fissuring at places. The lesions extended up to the muzzle and nostrils and were present on the buccal mucosa in the form of haemorrhagic ulcers. Sloughing of the affected epidermis due to necrosis was a common finding. Raised papules, pustules and scabs were also found in the perineal regions, teats and udder of some goats.

The animals were given symptomatic treatment with Terramycin (©Pfizer, Animal Pharma Private Limited, Mumbai @ 10 mg/kg body weight/day, intramuscularly for five days). Supportive treatment was given to weak and debilitated animals with Belamyl (©Zydus Animal Health Limited, Ahmadabad @ 1ml/adult intramuscularly once in a week for four

weeks). Topical dressings were done with Lorexane (©Virbac Animal Health India Private Limited, Mumbai) / Betadine ointment (©Win-Medicare Limited, New Delhi), Boric acid (JP Pharma, Jaipur) and potassium permanganate as per the need. Preventive and sanitary measures such as separation of healthy and infected animals, allocation of separate persons for working in the shed of clinical and healthy animals, proper washing of exposed hands and skin after handling the animals, overall cleaning of farm utensils and shed premises, restriction of animal movements from one shed to another shed etc. were suggested to the owner as well as animal handlers. The farmer was advised to sprinkle lime powder at the entry and around of the animal shed and to maintain overall cleanliness and hygiene. Soft and palatable diet was fed to the affected animals.

From two goats, scabs were collected by sterile scalpel and carried on ice to the laboratory for demonstration of the virus. The scabs were triturated in 0.01M phosphate buffered saline (PBS) and homogenized suspension was centrifuged at 5000 rpm for 10 min at 4°C. The supernatant was passed through 0.45 µm filter and used to inoculate a confluent monolayer of primary lamb testicle cultures and Vero cell line grown in 25 cm² tissue culture flasks in MEM (Modified Eagle's medium) supplemented with 10% foetal bovine serum (FBS), penicillin (100 U/ml) and streptomycin (100 mg/ml). Infected cells were kept in a 37°C incubator at 5% CO₂ level. Normal cell controls were maintained in a similar manner. The cells were observed daily for any cytopathic effects (CPE).

PCR was performed using DreamTaq Green PCR Master Mix (Thermoscientific, USA). Briefly, 50.0 µl of PCR mixture for each reaction contained 25.0 µl of 2X DreamTaq Green PCR Master Mix, 1.0 µl (20 pmol), each of forward and reverse primer (B2LF: TCCCTGAAGCCCTATTATTTTTGTG and B2LR: GCTTGCGGGCGTTCGGACCTTC, Hosamani et al., 2006), 18.0 µl of nuclease-free water and 5.0 µl of template DNA. Using a BioRad thermal cycler, the amplification parameters were set as 95°C for 5 min, followed by 35 cycles at 95°C for 50 s, 55°C for 50 s, and 72°C for 1min and a final extension phase of 72°C

for 15 min. The PCR products were analyzed on a 1% agarose gel.

RESULTS AND DISCUSSION

Clinical symptoms of contagious ecthyma started in the first week of June in Beetal goats which were brought from Punjab in May, 2012. All the Beetal goats (24 females and 1 male) were affected with respiratory distress, bilateral mucopurulent nasal discharge, pyrexia and anorexia. Five of the 25 Beetal goats including one male showed initial (phase I) lesions (Plate 1). Of the 20 kids only one male kid of Beetal goat was found affected with anorexia, fever and mild lesions. Twelve Beetal and two each of Jakharana and non-descript goats were affected with mild fever and partial anorexia with phase II lesions (Plate 2). Eight Beetal females showing severe lesions which were categorized as phase III lesions (Plate 3). The clinical signs observed in the present study were in accordance with the previous reports in sheep and goats (de la Concha-Bermejillo et al., 2003; Guo et al., 2003). The morbidity and the mortality of the disease were 30 in 163 (18.4%) and 2 in 163 (1.2%), respectively (Table 1). The disease has a very high morbidity; although mortality is rare and usually does not exceed 10%. Mortality rates of up to 93% have been reported in lambs (Zhao et al., 2010).

Table 1. Morbidity and mortality due to contagious ecthyma in goats

Breed	Number at risk	Morbidity (%)	Mortality (%)
Beetal	45	57.8	4.4
Jakhrana	25	8.0	0.0
Jamunapari	14	0.0	0.0
Sirohi	22	0.0	0.0
Totapari Local	20	0.0	0.0
Non-descript	37	5.4	0.0
Overall	163	18.4	1.2

The PCR generated an expected amplicon of 1206 bp in scab sample (Plate 4). The published primers are specific for orf virus and do not amplify the DNA of sheep and goat pox viruses that share close clinical manifestation with orf virus (Hosamani et al., 2006), and hence confirming the orf virus infection. The virus isolation however was not successful despite seven blind passages attempted in primary lamb testicle cultures and Vero cell line which could be

attributed to a loss of viral infectivity during transportation/storage of the samples.

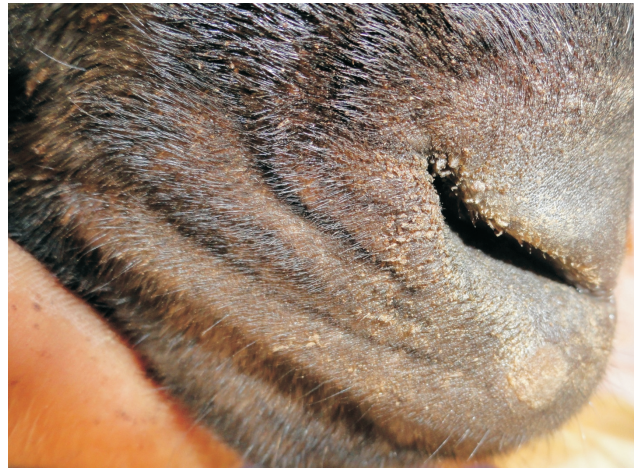

Plate 1. Phase I lesions of contagious ecthyma

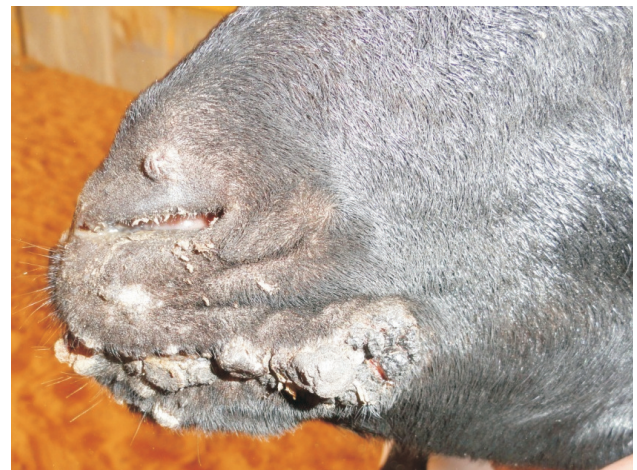

Plate 2. Phase II lesions of contagious ecthyma

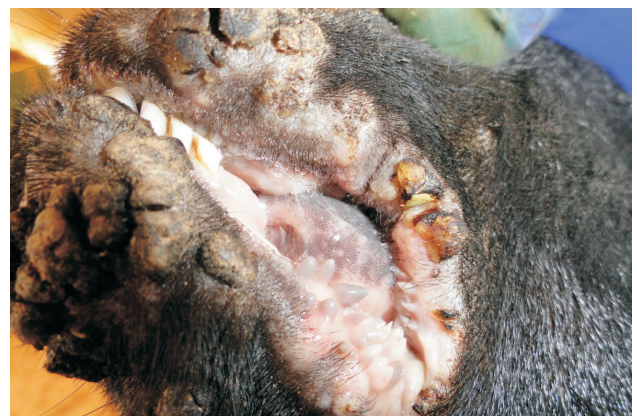

Plate 3. Phase III lesions contagious ecthyma

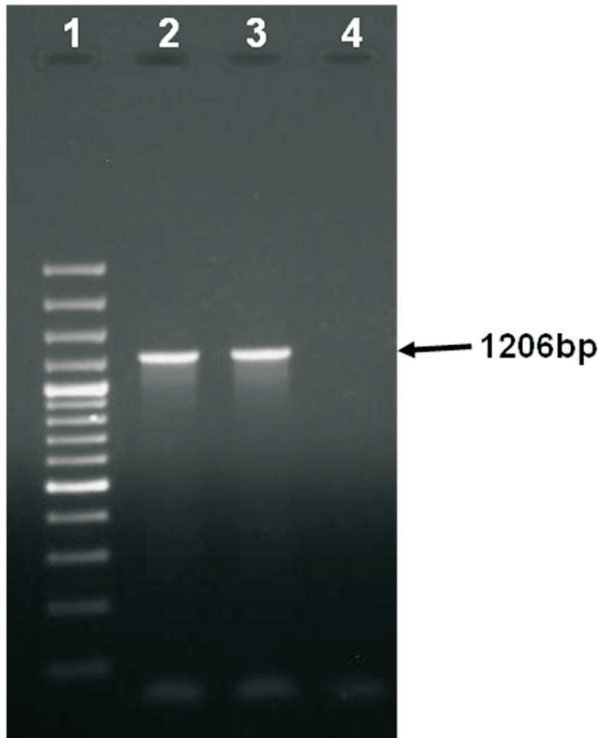


Plate 4. PCR amplification of B2L gene of orf virus (lane 1- 100bp DNA ladder, lane 2- scab 1, lane 3- scab 2, lane 4- non template control)

There is no suitable antiviral therapeutic schedule for contagious ecthyma as it is a self-limiting disease, symptomatic treatment with dressing of the lesions and application of local antiseptics are useful. Vaccination is the only option for the effective control of the infection. Although various types of vaccines are available against orf disease, live attenuated vaccines are always considered superior to others and are being used in some parts of the world where the disease is endemic (Nandi et al., 2011). However, currently neither vaccination is practiced nor is it produced in India.

In the present outbreak, the affected goats were quarantined from the healthy animals. The affected animals were treated following all bio-safety measures. Grouping of these animals made it easy to treat and provide veterinary care to the animals. Goats exhibiting phase III lesions were separated and the lesions were washed gently with 0.1% solution of potassium permanganate. The necrotic debris was removed gently and applied with iodine ointment on external surface. Borax solution (2%) was applied on

the buccal mucosa for the oral lesions. At the necrotic area of epidermis, topical antiseptic ointment was applied to repel flies, heal wounds and to prevent secondary bacterial infections. Goats showing phase II lesions were treated similarly as per the phase III lesion animals with 0.1% potassium permanganate, Terramycin and iodine ointments. Only a few animals showing phase I lesions required treatment with topical application. Rao and Bandyopadhyay (2000) reported similar therapeutic regime with topical and systematic antibiotics. In addition, farm owner was advised to follow strict preventive and precautionary measures to avoid spread of the infection in healthy flocks and animal handlers. The farm was visited once in a week to monitor therapeutic management and preventive measures until the recovery of animals. Animals recovered from the disease within 4 weeks without any mortality except 4.4% mortality in Beetal goats. The absence of mortality in the farm under study during the outbreak period was due to quick diagnosis and institution of effective management and veterinary care extended to the affected animals according to the severity of lesions. Further, the results suggested the possibility of breed susceptibility as the disease was very severe in Beetal goats than others, which, however, needs further investigation.

ACKNOWLEDGEMENTS

The authors thank the Director, ICAR-Central Sheep and Wool Research Institute, Avikanagar for providing the facility to carry out this research work.

REFERENCES

- Abrahao, J.S., Campos, R.K., Trindade, G.S., Guedes, M.I.M., Lobato, Z.I.P., Mazur, C., Ferreira, P.C.P., Bonjardim, C.A., and Kroon, E.G. 2009. Detection and phylogenetic analysis of *Orf* virus from sheep in Brazil: a case report. *Virology Journal* 6: 47.
- Bath, G.F., van Wyk, J.A. and Pettey, K.P. 2005. Control measures for some important and unusual goat diseases in southern Africa. *Small Ruminant Research* 60: 127-140.
- de la Concha-Bermejillo, A., Guo, J., Zhang, Z. and Waldron, D. 2003. Severe persistent orf in young goats. *Journal of Veterinary Diagnostic Investigation* 15: 423-431.
- Guo, J., Zhang, Z., Edwards, J.F., Ermel, R.W., Taylor Jr., C. and de la Concha-Bermejillo, A. 2003. Characterization of a North American orf virus isolated from a goat with

- persistent, proliferative dermatitis. *Virus Research* 93: 169-179.
- Hosamani, M., Bhanuprakash, V., Scagliarini, A. and Singh, R.K. 2006. Comparative sequence analysis of major envelope protein gene (B2L) of Indian orf viruses isolated from sheep and goats. *Veterinary Microbiology* 116: 317-324.
- Mondal, B., Bera, A.K., Hosamani, M., Tembhurne, P.A. and Bandyopadhyay, S.K. 2006. Detection of orf virus from an outbreak in goats and its genetic relation with other parapoxviruses. *Veterinary Research Communications* 30: 531-539.
- Nandi, S., De, U.K. and Chowdhury, S. 2011. Current status of contagious ecthyma or orf disease in goat and sheep- a global perspective. *Small Ruminant Research* 96: 73-82.
- Pye, D. 1990. Vaccination of sheep with cell culture grown orf virus. *Australian Veterinary Journal* 67: 182-186.
- Ramesh, A., Vadivoo, V.S., Suresh Babu, S. and Saravanabava K. 2008. Confirmatory diagnosis of contagious ecthyma by amplification of the GIF/II-2 gene by PCR. *Tamilnadu Journal of Veterinary and Animal Sciences* 4: 208-210.
- Rao, T.V.S. and Bandyopadhyay, S.K. 2000. A comprehensive review of goat pox and sheep pox and their diagnosis. *Animal Health Research Reviews* 1: 127-136.
- Thomas, K., Tompkins, D.M., Sainsbury, A.W., Wood, A.R., Dalziel, R., Nettleton, P.F. and McInnes, C.J. 2003. A novel poxvirus lethal to red squirrels (*Sciurus vulgaris*). *Journal of General Virology* 84: 3337-3341.
- Venkatesan, G., Balamurugan, V., Bora, D.P., Yogisharadhya, R., Prabhu, M. and Bhanuprakash, V., 2011. Sequence and phylogenetic analyses of an Indian isolate of orf virus from sheep. *Veterinary Italiana* 43: 323-332.
- Wilson, D.J., Scott, P.R., Sargison, N.D., Bell, G. and Rhind, S.M. 2002. Effective treatment of severe facial dermatitis in lambs. *Veterinary Record* 150: 45-46.
- Zhao, K., Song, D., He, W., Lu, H., Zhang, B., Li, C., Chen, K. and Gao, F. 2010. Identification and phylogenetic analysis of an Orf virus isolated from an outbreak in sheep in the Jilin province of China. *Veterinary Microbiology* 142: 408-415.
- Zheng, M., Liu, Q., Jin, N., Guo, J., Huang, X., Li, H., Zhu, W. and Xiong, Y. 2007. A duplex PCR assay for simultaneous detection and differentiation of Capripoxvirus and Orf virus. *Molecular and Cellular Probes* 21: 276-281.