

## ***Benedenia epinepheli* (Yamaguti 1937), A Monogenean Parasite in Captive Broodstock of Grouper, *Epinephelus tauvina* (Forsk.)**

**K.P. JITHENDRAN, K.K. VIJAYAN, S.V. ALAVANDI and M. KAILASAM**

*Central Institute of Brackishwater Aquaculture*  
75, Santhome High Road  
Chennai - 600 028  
India

### **Abstract**

Grouper (*Epinephelus* spp.) is one of the most economically important cultured marine fish in Asia, particularly in Thailand, Malaysia, Philippines, Singapore, Indonesia and Taiwan. Over 10 species of grouper fish have been cultured in the region. In India, greasy grouper fish, *Epinephelus tauvina* is gaining importance as a candidate species for marine and coastal aquaculture. A study conducted on wild and captive broodstock of grouper (size range, 15 - 40 cm; body weight 0.2 - 4 Kg) collected from sea near Chennai revealed infection with monogenean parasites in a large number of fishes (27%). The present communication is the summary of the prevalence, taxonomy and pathology of these infection encountered in *E. tauvina* and the containment strategies. Acute infection of ectoparasitic monogeneans, *Benedenia* sp. was observed in 19 wild grouper (*E. tauvina*) fish and 12 of the broodstock fish maintained in captivity. The parasite measured 2.05 - 3.29 x 0.66 - 1.33 mm and was found to infest the gills, fins and skin of the fish. Fishes with advanced infestation were characterized by erratic swimming behaviour and restlessness. The fish with severe infections had small focal haemorrhages on the body, which often resulted in secondary bacterial infection leading to the sloughing of the skin and excessive mucus secretion. A description of the parasite and its pathobiology is discussed. Successful treatment of monogenean infection was carried out by short bath treatment with 100 ppm formalin. Freshwater bath was found effective in dislodging the parasite from the fish. Hydrogen peroxide (150 ppm) bath was found to be effective but revival of parasite was observed after short bath.

## Introduction

The grouper, *E. tauvina* is an important cultured fish species especially in South East Asian countries (Liao et al. 2001). In India, there is a considerable interest in farming the grouper. However, maintenance of a healthy fish population depends on knowledge of the disease causing agent and the implementation of an effective disease control programme. Parasitic diseases pose great problem in the breeding programme of these fishes. Ectoparasites, especially monogenean infection causes serious damage to the fishes in captivity. Leong and Wong (1988), Al-Marzouq and Al-Rifae (1994) and Koesharyani et al. (1999) reported the parasitic problems of grouper in Malaysia, Kuwait and Indonesia, respectively. However, the parasitic problems in wild population of grouper fishes in India or in captivity have not been well documented. The present communication is to report the occurrence of monogenean infections, *B. epinepheli* encountered in *E. tauvina*, pathology of these infection and the strategies to control the parasitic infestation.

## Materials and Methods

Adult grouper, *E. tauvina* (n = 19; size range: 15 - 40 cm, mean  $28.5 \pm 8.15$ ; body weight 0.2 - 4 kg, mean  $1.82 \pm 1.12$ ) collected from the wild near Chennai coast of India were brought alive and examined for their parasites. Twelve of the broodstock fishes (27 - 40 cm, 2.5 - 3.5 kg) originally collected from the same locality, but maintained in 500 ton outdoor concrete tank (27 - 28°C, 30 - 32 ppt) for the captive broodstock development programme were also examined after death for comparison. Fish were examined thoroughly for ecto and endoparasites. Wet mounts of scrapings from the skin, fins and gills were prepared and examined under microscope. The gills were dissected out and gill filaments were examined under stereozoom microscope. Similarly, all the visceral organs were also dissected out and examined for any internal parasites. A few specimens of parasites were examined live and details were recorded. Ten specimens of each collections were measured for the range and the mean  $\pm$  standard deviation (SD). A few of the specimens were washed in normal saline and preserved in 70% ethanol, stained with borax carmine, dehydrated in graded alcohol series and finally cleared in clove oil before mounting in Canada balsam. Photomicrographs were taken using WILD MPS 46 microcamera fitted to a Leica Laborlax S microscope.

Some of the infected fishes were maintained in freshwater treatment for 15 min, H<sub>2</sub>O<sub>2</sub> (150 ppm) and formalin (100 ppm) for 30 min in a

50 L fibre glass tank to check the effect of treatments on parasites affecting the fishes.

## Results and Discussion

In the present paper the occurrence of monogenean parasites belonging to the family capsalidae were recorded in wild and captive broodstock fishes of grouper. Large number of readily visible, red colored parasites were found attached to the gill filaments and/or skin by its haptors. Infected gills were found off colour, covered with mucous layer. Frayed out margins of the gills were common occurrences. Occasional haemorrhagic spots were also noticed. Loss of scales was detected in the head region near the eyes. Morphological characteristics of the trematode resembled that of the monogenean, *Benedenia* sp. described by Tripathi (1957). Heavily infested fish showed excessive mucus secretions on the body surface. Some of the infected fishes showed secondary bacterial infections on skin and other ectoparasitism like *Caligus* and leech infestation. Comparatively less parasite load (6-28) per fish was observed in wild fishes and the intensification in tanks led to more parasite load (18-68).

### Description of the parasite

The parasite was flattened in shape with elongated body and measured 2.05 -3.29 x 0.66 - 1.33 mm in length and width, respectively (Table 1). Two pairs of eyes were present; anterior pair being smaller than the posterior. The posterior end is armed with disc like opisthaptor with hooks (Figs. 1a and b). The anterior end possesses one pair of suckers with an average diameter of 0.19 mm. The specimens were identified

Table 1. Morphometry of *Benedenia epinepheli*, the monogenean parasite infecting grouper (*Epinephelus tauvina*)

Parameters	Measurements (mm), n = 20	
	Range	Mean ± SD
Body length	2.05 - 3.29	2.73±0.39
Body width	0.66 - 1.33	0.97±0.20
Opisthaptor	0.45 - 0.76	0.59±0.10
Suckers	0.19 - 0.27	0.22±0.03
Testes*	0.19 - 0.32 x 0.38 - 0.57	0.28±0.05 x 0.46±0.06
Ovary	0.10 - 0.25	0.20±0.05
Pharynx	0.13 - 0.25	0.20±0.04

\*Ovoidal in shape (width x length), average of one pair

as *B. epinepheli* from the presence of the flap and general morphology (vagina present).

*B. epinepheli* was first reported in 1937 from wild fishes of Japan (Yamaguti 1963). Since then, the parasite has been reported worldwide from subtropical and tropical areas with low host-specificity and several species of grouper acting as hosts (Leong and Wong 1988, Al-Marzouq and Al-Rifae 1994, Koesharyani et al. 1999, APEC/SEADEC 2001, Leong 2001). However, pathobiological information on grouper and their parasite is fragmentary in India. Monogeneans are generally highly host specific (Kabata 1970) and the wide range of host species with low specificity is quite exceptional in monogenea. Among the members of the genus *Benedenia*, *B. epinepheli* and *B. hawaiiensis* seem to be the only 2 species with a very high host range. A total of 25 species of fish serve as hosts for *B. epinepheli* (Ogawa et al. 1995).

Heavy infection of *B. epinepheli* caused not only haemorrhagic and abrasive lesions, but also mortalities in cultured marine fish due to severe necrosis of the gill tissues possibly resulting in suffocation (Leong 2001).

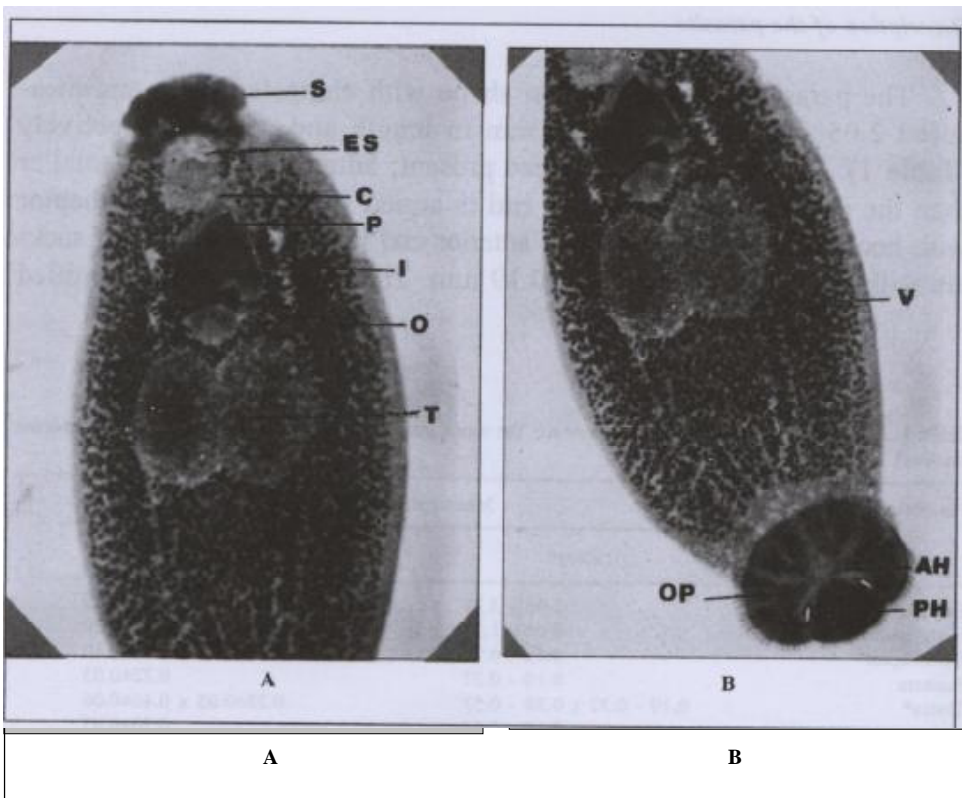


Fig. 1. *B. epinepheli* of grouper, anterior (a) and posterior end (b); 100 x [OP: opisthaptor, PH: posterior hooks, AH: anterior hooks, V: vitellaria, S: suckers, ES: eye spot, C: cirrus, P: pharynx, I: intestine, O: ovary and T: testes ]

High intensities of monogeneans resulting in secondary infections of *Vibrios* have been reported (Leong and Wong 1988). Conditions of overcrowding and adverse ambient conditions promote epizootic diseases. Further, the population of flukes is often much greater in confined fishes and hence maintenance of fish health in captivity is a major concern. Under suitable environmental conditions the monogeneans multiply very fast as the organisms are hermaphrodite, and life cycle is direct and can spread to fresh host by contact from one host to another. The fish diagnostician should attempt to identify the species of monogenean flukes; firstly, some fluke species are not susceptible to the usual therapeutic procedures and hence attempts to treat them with a useless chemical may be time consuming, expensive and of little help to the fishes; secondly, to have a pathogen inventory in a locality and also knowledge of the environment of each species (temperature, pH, salinity and other physical factors) may assist in controlling these organisms.

The freshwater bath for 15 min. was found to be effective in dislodging the parasite from the gills and skin of the broodstock. Successful treatment of monogenean infection was carried out by short bath treatment with 100 ppm formalin. Hydrogen peroxide (150 ppm) bath was found to be effective but revival of parasite was observed after short bath. A detailed investigation of freshwater bath treatment and other disinfectants using chemicals and the tolerance by the host fish are needed on a large number of fishes. Further, the ability of *B. epinepheli* to cause death of cultured fishes during heavy infection and its low host specificity, ubiquitous distribution and high susceptibility of large number of marine fishes are indicative of the parasite's great potential to become a disease problem in tropical countries.

### Acknowledgments

The authors are thankful to the Director and Head, Nutrition, Physiology and Pathology Section, Central Institute of Brackishwater Aquaculture (Chennai, India) for providing the facilities to carry out this study.

### References

- Al-Marzouq, A. and K. Al-Rifae. 1994. *Benedenia* sp. a monogenetic parasite of cultured brown-spotted grouper, *Epinephelus tauvina*, in Kuwait. *Journal of Aquaculture Tropics*, 9:255-258.
- APEC / SEAFDEC. 2001. Husbandry and Health Management of Grouper. APEC, Singapore and SEAFDEC, Iloilo, Philippines. 94 p.
- Kabata, Z. 1970. Parasitology of fishes. T.F.H. Publications. Inc. Ltd. Hongkong pp. 104-116.
- Koesharyani, I., Zafran, K. Yuasa and K. Hatai. 1999. Two species of Capsalid monogeneans infecting cultured humpback grouper *Cromileptes altivelis* in Indonesia. *Fish Pathology*, 34:165-166.

- Leong, T.S. 2001. Chronology of diseases in cultured marine finfishes. *Aquaculture Asia*, 6:10-13.
- Leong, T.S. and S. Y. Wong. 1988. A comparative study of the parasite fauna of wild and cultured grouper (*Epinephelus malabaricus* Bloch et Schneider) in Malaysia. *Aquaculture*, 68:203-207.
- Liao, I.C., H.M. Su and E.Y. Chang. 2001. Techniques in fin fish larviculture in Taiwan. *Aquaculture* 200:1-31.
- Ogawa, K., M.G. Bondad-Reantaso, H. Wakabayashi. 1995. Redescription of *Benedenia epinepheli* (Yamaguti 1937) Meserve 1938 (Monogenea: Capsalidae) from cultured and aquarium marine fishes of Japan. *Canadian Journal of Fisheries and Aquatic Sciences*, 52:62-70.
- Tripathi, Y.R. 1957. Monogenetic trematodes from fishes of India. *Indian Journal of Helminthology*, 9:1-149.
- Yamaguti, S. 1963. *Systema Helminthum*. Vol. IV, Monogenea and Aspidocotylea. John Wiley and Sons, Interscience Publishers, New York, 699 p.