

A Rare Case of Rhabdomyoma in Milk Fish, *Chanos chanos* (Forsskål, 1775) Associated With Iridoviral Infection

R. Ananda Raja¹, K. P. Jithendran, A. Panigrahi, J. K. Sundaray, G. Biswas, Debasis De, T. K. Ghoshal and Sujeet Kumar

Kakdwip Research Centre of CIBA, Kakdwip, South 24 Parganas, West Bengal 743 347

(Received : 07-03-2011;

Accepted : 16-05-2011)

The first documented rhabdomyogenic tumor in fish was described in a cut-throat trout, *Oncorhynchus clarkii* by Adami (1908). Since then documented cases of rhabdomyoma or rhabdomyosarcomas in fish have grown steadily; however, many of these tumors have developed in response to prolonged exposure to mutagenic compounds during carcinogenicity trials (Hawkins *et al.* 1989; Bunton and Wolfe 1996). During routine screening of brackishwater fishes for irido virus infection and viral nervous necrosis (VNN), a case of rhabdomyoma in a milk fish, *Chanos chanos* (Forsskål, 1775) was observed. This paper describes the spontaneous coincidence of rhabdomyoma and irido viral infection.

Materials and Methods

Four months cultured milk fish, *Chanos chanos* showing tumor was collected from culture ponds of this centre. The pond was fed with low cost pelleted feed prepared from locally available feed ingredients as supplementary feed @ 2-5% bw. The salinity and the temperature were ranging from 10-16 ppt and 27-31°C respectively. The morphometric parameters of the fish were recorded. Wet mounts of skin and gill smears were prepared and examined for endo- and ecto-parasites. The fish was euthanized and post mortem was conducted. Tissues of spleen, brain, liver, kidney, gill and tumor mass were preserved in 10% neutral buffered formalin for routine histopathology and the tissues of brain and spleen

in 95% ethanol. Blood samples and swabs from kidney and other vital organs were collected for bacteriological examination.

DNA from the tissues was extracted using DNAzol (Invitrogen). The extracted DNA were individually dissolved in 100ml nuclease free water and stored at -20°C until use. PCR was carried out in 25 µl of total reaction volume consisting of 2 µl of the total DNA, 20 pmol each of forward and reverse primers (2F-5' TACAACATGCTCCGCCAAGA 3' and 1R-5' GCACCAACACATCTCCTATC 3' respectively) and 2X PCR master mix (Genei, Bangalore). The cyclic conditions followed in a thermocycler (ependorf, Germany) was, initial denaturation at 94°C for 3 min. followed by 35 cycles at 94°C for 30 sec, 58°C for 40 sec. and 72°C for 1 min. as denaturation, annealing and extension temperatures, respectively. The final extension was at 72°C for 10 min. The PCR products were visualized in 2% agarose gel. RT-PCR was performed from brain samples against VNN using RT-PCR kit for viral nervous necrosis.

Results and Discussion

Morphologically, the milk fish (length 157 mm; body weight 123.2 g) had a muscle tumor subcutaneously along the right lateral side of the spinal cord below the dorsal fin. Sagittal section of the tumor was 17 x12 x7mm with gelatinous appearance and encapsulation. Based on the histopathological investigation, the tumor was diagnosed as rhabdomyoma. The

¹Corresponding author : Email : anandarajars@gmail.com

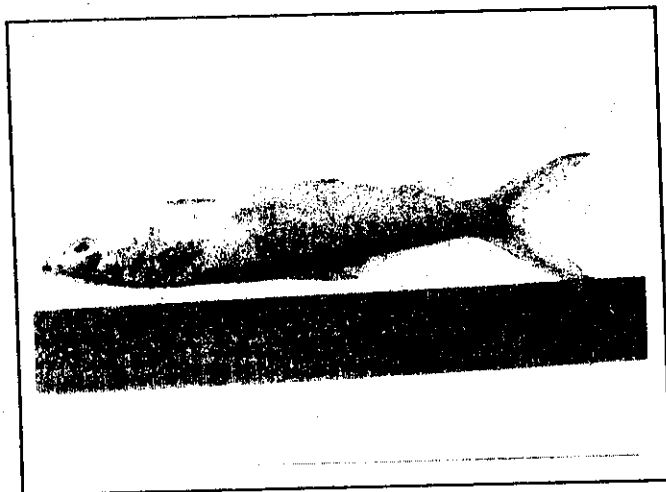


Fig 1. *Chanos chanos* showing rhabdomyoma subcutaneously along the right lateral side.

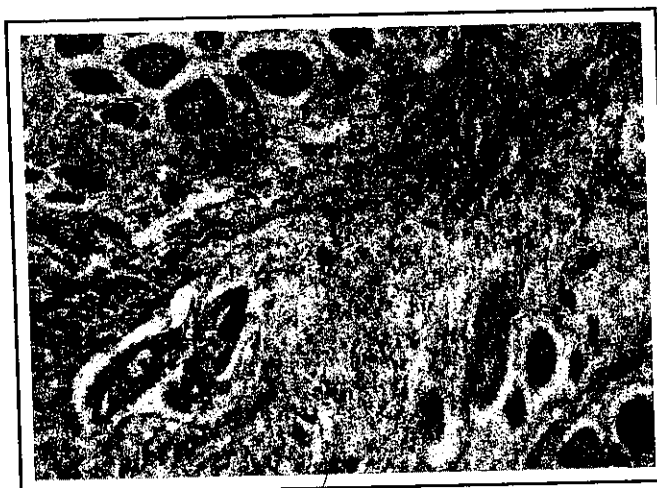

Fig 2. Histological section of the muscles showing spindle shaped neoplastic cells with long or oblong nuclei. Fibrous tissue septa divided the muscle bundles into lobules with well formed blood vessels (arrows). 40 x, H&E.




Fig 3. Agarose gel electrophoresis of the PCR products specific to iridovirus in *Chanos chanos* (Lane M-100 bp marker; Lane 1- *Chanos chanos* spleen from a polyculture pond showing positive; Lane 2 - Positive control; Lane 3 - Negative control).

neoplastic cells were long and spindle shaped with oval and oblong nuclei. They were arranged in whorls. Fibrous tissue septa divided the muscle bundles into lobules with well formed blood vessels. No metastasis was observed in the vital organs. Detailed laboratory investigations for parasitological and bacteriological etiology did not reveal major findings. PCR screening of spleen showed positive for iridoviral infection while brain

sample for VNN was negative.

The main causes of neoplasms in fish are species predisposition as in Ictaluridae (Grizzle *et al.* 1995), virus (Schmale *et al.* 2002) and chemical carcinogens (Knusel *et al.* 2007). The age could be a predisposing factor (Grizzle *loc. cit.*) and the low temperatures usually reduce the incidence of neoplasms in fish exposed to chemical carcinogens (Hendricks *et al.* 1984). Genetic predispositions for the development of certain tumors are possible (Knusel *loc. cit.*). In the present study, the fish seeds were wild in origin and the culture was 4 months old in ponds at the time of collecting the fish. The temperature of the culture ponds was between 27 and 31°C. So, the age and temperature could have not played as predisposing factors in this case since there was only single case of rhabdomyoma whilst other fishes were apparently normal. Moreover, no other fish showed any oncogenic lesions from the population even 3 months later at the time of harvest. Iridovirus has been identified as one of the most important viral pathogens, particularly at the fry and fingerling stages in barramundi, *Lates calcarifer* (Bloch) as reported by Lai *et al.* (2008). It causes severe economic loss in farmed marine fish species. In

an afflicted fish, Irido virus causes lethargy, bleeding on the epidermal surface, severe anemia, cell hypertrophy in spleen, and finally death (Syunichirou *et al.* 1998). But, in the present case no such symptoms were observed. So, the occurrence of rhabdomyoma in the present case is spontaneous and coincident but not of viral origin.

References

- Adami, J.G. (1908) *Montreal Med. J.*, **37**: 163.
- Bunton, T.E. and Wolfe, M.J. (1996) *Toxic. Path.*, **24**: 323.
- Grizzle, J.M., Bunkley-Williams, L. and Harshbarger, J.C. (1995) *J. Aqua. Ani. Health.*, **7**: 178.
- Hawkins, W.E., Walker, W.W., Lytle, J.S., Lytle, T.F. and Overstreet, R.M. (1989) *Aqua. Toxic.*, **15**: 63.
- Hendricks, J.D., Meyers, T.R. and Shelton, D.W. (1984) *National Can. Inst. Monograph.*, **65**: 321.
- Knusel, R., Brandes, K., Lechleiter, S. and Schmidt-Posthaus, H. (2007) *Vet. Path.*, **44**: 237.
- Lai, Y.S., Chiou, P.P., Chen, W.J., Chen, Y.C., Chen, C.W., Chiu, I.S., Chen, S.D., Cheng, Y. H. and Chang, C.Y. (2008) *J. Fish Dis.*, **31**: 825.
- Schmale, M.C., Gibbs, P.D.L. and Campbell, C.E. (2002) *Dis. Aqua. Org.*, **49**: 107.
- Syunichirou Oshima, Jun-ichiro Hata, Noritaka Hirawawa., Taro Ohtaka., Ikuo Hirono., Takashi Aoki. And Shinya Yamashital. (1998) *Dis. Aqua. Org.*, **32**: 87.

Indian Vet. J., October 2012, 89 (10) : 107 - 108

Effect of Insemination Timing on Fertility in Broiler Breeders*

D. Singh¹ and M.C. Yadav

Project Directorate on Poultry, Rajendranagar, Hyderabad 500030, Andhra Pradesh

(Received : 28-01-2011;

Accepted : 07-05-2011)

Proper timing of insemination is important to achieve high fertility and it is generally recommended when no hard – shelled egg is present in the uterus, or at least within three hours of oviposition (Davtyan *et al.*, 1986). Brillard *et al.* (1987) stated that hens inseminated 1 h after oviposition retained lower percentage of initial dose of semen than hens inseminated at 5 to 6 h after oviposition. The present study was taken up to analyze the effect of timing of insemination on fertility in broiler breeders under local agroclimatic conditions.

Materials and Methods

Krishibro broiler parent lines maintained at Project Directorate on Poultry, Hyderabad, were used in the present study. Inseminations were carried out from 8 AM to 10 PM at two hourly intervals with pooled fresh semen collected from twenty males. Eight groups, each consisting of twelve hens were inseminated at different timings as mentioned above. The fertility was ascertained by breaking open the egg and inspecting for evidence at 7th day of incubation. The data were subjected to one way

*Part of Ph.D. thesis submitted to Dr. Bhimrao Ambedkar University (Formerly Agra University) Agra

¹Corresponding author : Email : daryabsingh@yahoo.com