

# TREATMENT OF CYSTIC OVARIAN DEGENERATION IN INDIAN CAMEL (*CAMELUS DROMEDARIUS*)

S. Vyas, A.K. Rai and N.D. Khanna

National Research Centre on Camel,  
Post Box - 07, Jorbeer,  
Bikaner (Raj.) 334 001.

Cystic ovarian degeneration is one of the important causes of infertility and affects a high proportion of dairy cows, extending the intercalving periods and leads to economic losses to the animal owners. Cystic condition arises due to failure of the Hypophysis to release sufficient amount of luteinizing hormone (L.H.) to produce ovulation and proper development of corpus luteum (Roberts, 1971).

Two adult multiparous she camels belonging to the National Research Centre on Camel, Bikaner was observed to express abnormal sexual behaviour. They used to mount on other females. The history revealed that the animals did not conceive during the previous breeding season. Ultrasound examination using 5 MHz endovaginal sector probe of scanner-200 (Pie-Medicals) revealed presence of single big follicular cyst in the right ovary of both the animals. The cysts were thick walled, measuring 6.77 cm (Fig.1) and 7.42 cm respectively in diameter. The animals were reexamined after 7 days but there was no change in the size and form of these cysts.

The animals were administered Buserelin acetate 0.042 mg (Receptal 10 ml, Hoechst) intra muscularly. No cyst could

be observed after 3 days of the treatment. The animals conceived in the subsequent breeding season. This is the first report of cystic ovarian degeneration in Indian camel.

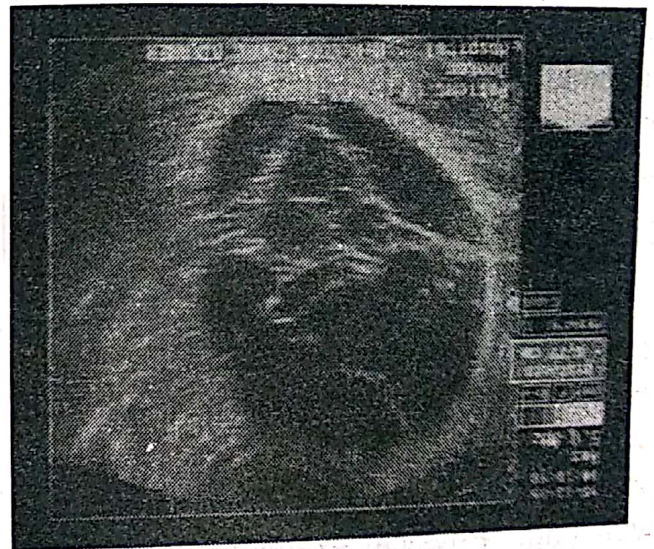


Fig.1. Follicular Cyst (6.77 cm)

## Summary

Successful treatment of two cases of Cystic ovarian degeneration in camels is reported.

## Reference

Roberts, S.J (1971)... Veterinary Obstetrics and Genital diseases, 2nd edn. C.B.S. Publishers and distributors, Delhi.