



Fetal Mummification in Domestic Animals: A Critical Review

Vikram R.¹, Vivek Joshi¹, Amit Khatti², Babu M.³, Kamni Paia Biam¹ and Deepandita Barman⁴

¹Scientist, ICAR- National Research Centre on Mithun, Medziphema-797 106, Nagaland, INDIA

²Ph.D. Scholar, ICAR- Indian Veterinary Research Institute, Izatnagar-243 122, Uttar Pradesh, INDIA

³Assistant Professor, Veterinary College, Hassan, KVAFSU, Bidar-585 401, Karnataka, INDIA

⁴Assistant Professor, Lakhimpur College of Veterinary Science, AAU, Jorhat-785 013, Assam, INDIA

*Corresponding Author: vikram.r@icar.gov.in

How to cite this paper: Vikram, R., Joshi, V., Khatti, A., Babu, M., Biam, K., & Barman, D. (2020). **Fetal Mummification in Domestic Animals: A Critical Review.** *International Journal of Livestock Research*, 10(11), 15-22. doi: <http://dx.doi.org/10.5455/ijlr.20200727051057>

Received : Jul 27, 2020
Accepted : Sep 20, 2020
Published : Nov 30, 2020

Copyright © Vikram *et al.*, 2020

This work is licensed under the Creative Commons Attribution International License (CC BY 4.0). <http://creativecommons.org/licenses/by/4.0/>



Abstract

Fetal mummification is the unusual and most important gestational disorder in domestic animals with the highest incidence in multiparous and polytocous species like swine (up to 4%). The fetal mummification is different in monotocous and polytocous species. In cattle and buffalo, it is commonly observed between 4th to 8th month of gestation. The fetal death without abortion, persistent corpus luteum and progesterone influence collectively lead to the formation of the mummified fetus. The two notable forms of mummification in domestic animals include haematic and papyraceous types. The etiology is multifactorial and different conditions are held responsible for the occurrence of fetal mummification in each species. The common causes include genetic or chromosomal abnormalities, placental defects, infectious agents, abnormal hormonal concentrations, and drugs. Transrectal palpation, radiography, and ultrasonography are useful clinical tools for the diagnosis of mummification. The treatment protocols and management strategies differ between the species. The prevention of fetal mummification is possible by practicing good hygiene and sanitation, periodically following the standard vaccination protocols, and adopting the recommended reproductive monitoring programmes.

Keywords: Fetal Mummification, Haematic, Papyraceous, Polytocous, Vaccination

Introduction

Fetal mummification is one of the important gestational disorders in domestic species where a fetus dies and along with fetal debris remains in the dam's uterus beyond the normal length of gestation. Multiparous and polytocous species like swine exhibit a higher incidence of mummification. Besides, it has been reported in several other species, including the cattle, buffalo, goat, sheep, horse, bitch, and cat. In cow and buffalo, the fetal death without abortion and persistent corpus luteum (PCL) at the end of the first and beginning of the second trimester of gestation result in autolytic changes in the fetus. The shrinkage of the uterus and the fetus occurs gradually with the absorption of the placenta and fetal fluids forming mummy within the uterus. The cervix remains tightly closed in this condition and the fetus will be sterile (Purohit and Gaur, 2011). The mummification keeps the uterus quiescent through the continued presence of progesterone from a (PCL) (cow), functional placenta (mare), or some exogenous (progesterone injections). The cattle and buffalo exhibit anoestrus as a mummified fetus remain in the uterus under the persistent effect of progesterone. The mummified fetus associated with a PCL is noticed mainly in cows and buffaloes, rarely in goats. In pig, goat, sheep, dog, and cat, one or multiple fetuses will be affected and delivered at the time of normal parturition.

Incidence

The breed and history of the previous incidence are considered to be risk factors for higher incidence. The fetal mummification has an incidence of up to 2% and 0.01% in cattle and buffalo, respectively (Barth, 1986; Modi *et al.*, 2011). The Brazilian swine herds and French herds exhibited a prevalence of 3.45% and 3.9%, respectively (Cozler *et al.*, 2002; Borges *et al.*, 2005). Fetal mummification in goats and sheep is unusual and affects either single or multiple fetuses. The incidence in horses is very rare and a substantial study of abortion in the mares reported only two cases (0.007%) of fetal mummification (Tengelsen *et al.*, 1997). Similar to cows, in horses mummification occurs between the end of the first trimester and last trimester of pregnancy. The incidence in dogs and cats is low with sporadic reports.

Etiology

The causes of fetal death and mummification are manifold and impossible to determine as the time of fetal death is not known (Table 1). The autolysis followed by mummification of fetus and membranes poses difficulty in the determination of causative agents. The common causes of fetal mummification are genetic or chromosomal abnormalities, placental defects, infectious agents, abnormal hormonal concentrations, and drugs in most of the domestic animals. The infectious agents like *Campylobacter fetus*, fungi, *Leptospira* spp., and BVD-MD virus causing fetal death without abortion may result in mummification in cattle (Drost, 2007). Likewise, most of these diseases are reported in buffaloes and might induce a similar fatal outcome to the fetus in buffaloes (Martuciello *et al.*, 2009). Furthermore, the ingestion of toxic plants is also a can also lead to fetal death and mummification in ruminants (Smith, 1979). The torsion of the fetal umbilical cord leading to compression followed by fetal hypoxia can sometimes be a cause of mummification. In sheep and goats, fetal mummification is most often associated with infectious diseases, especially *Coxiella* infection (Lefebvre, 2015). The deficiency of energy and protein during 90–120 days of gestation also leads to mummification. In swine, it is related to poor management, underfeeding, and infectious diseases (Lefebvre, 2015). In horses, mummification is mainly associated with the twin fetus death due to the lack of sufficient space in the uterus for the survival of both fetuses. The infectious agents seem to be largely responsible for fetal mummification in dogs and cats. The mummification process usually makes bacterial and viral analysis, biopsy, and chromosome analysis very difficult (Elmore, 1992). Interestingly, cattle and buffalo uteri which are examined and cultured are sterile and free of microorganisms. The endometrium will be involuted and appears normal which is further supported by the fact that cows usually conceive in the subsequent estrus after the removal of the mummified fetus.

Table 1: Species-wise etiology of fetal mummification in domestic animals

Species	Reference	Infectious causes	Non -infectious causes
Cow and Buffalo	(Smith, 1979; Drost, 2007; Martuciello <i>et al.</i> , 2009; Lefebvre, 2015)	1. <i>Campylobacter fetus</i>	1. Umbilical torsion
		2. Molds	2. Uterine torsion
		3. <i>Leptospira</i> spp.	3. Defective placentation
		4. Enteroviruses	4. Interplacental hemorrhage
		5. BVD-MD	5. Failure of placental function
		6. <i>Neospora caninum</i>	6. Toxic plants (eg. <i>Pieris japonica</i>)
			7. Genetic anomalies
			8. Abnormal hormonal profiles
			9. Chromosomal abnormalities
			10. Deficiency of uridine monophosphate synthase (DUMPS)
Swine	(Lefebvre, 2015)	1. Porcine parvovirus (PPV)	1. Larger litter size
		2. Aujeszky's disease/pseudorabies virus (AD/PRV)	2. Placental insufficiency
		3. Encephalomyocarditis virus (EMCV)	3. Mycotoxins
		4. Swine erysipelas	4. Adverse environmental conditions
		5. Japanese encephalitis virus (JEV)	
		6. Porcine circovirus 2 (PCV2)	
		7. Porcine reproductive and respiratory syndrome virus (PRRSV)	
		8. Swine fever virus (SFV; African and classical)	
		9. Swine influenza virus (SIV)	
		10. Teschovirus	
Sheep and goat	(Luedke, 1985; Broaddus <i>et al.</i> , 2009; Dubey, 2009; Lefebvre, 2015)	1. <i>Toxoplasma gondii</i>	1. Energy and protein deficiency
		2. <i>Chlamydophila abortus</i>	2. Trauma causing fetal death (eg. prepubic tendon rupture)
		3. Bluetongue	
		4. BVD	
		5. Border disease	
		6. <i>Coxiella</i> infection	
Horses	(Threlfall, 2005; Lefebvre, 2015)	Nil	1. Twinning 2. Ultrasonography-guided twin reduction
Dogs	(Hashimoto <i>et al.</i> , 1982; Planellas <i>et al.</i> , 2012; Lefebvre, 2015)	1. Canine herpesvirus (CHV)	1. Hypothyroidism
		2. Canine papillomavirus type 1 (CPV1)	2. Chromosome and development abnormalities of the fetus
		3. <i>Toxoplasma</i>	3. Exogenous drugs
Cats	Planellas <i>et al.</i> , 2012; Lefebvre, 2015)	1. Feline panleukopenia virus	1. Trauma leading to uterine rupture
		2. Feline leukemia virus	2. Exogenous drugs
		3. Feline rhinotracheitis virus	3. Uterine torsion
		4. Feline infectious peritonitis virus	

Pathophysiology

The formation of fetal mummy occurs gradually over weeks to months and depends upon the fetal age at the time of the death. In cattle and buffaloes, after fetal death when the placental caruncles start to involute, hemorrhage occurs between the endometrium and fetal membranes. This leaves a reddish-brown, gummy, tenacious mass of autolyzed red cells, clots, and mucus after absorption of plasma. The brownish mass of viscous adhesive material coats the fetus and hence the mummification is known as haematic or chocolate mummification (Fig. 1A & 1C). It is common between the 4th to 8th month of gestation but most cases occur during the 5th and 6th month in all age groups and various breeds of cows and buffaloes. The haematic mummification is also reported in dogs (Vikram *et al.*, 2015) and horses (Pizzigatti *et al.*, 2012). In some instances, the mummy will be dry, shriveled with the stiff fetoplacenta unit and no exudate is called papyraceous mummification, reported in cattle (Fig. 1B), buffaloes, dogs, cats, and sharks (Arthur *et al.*, 1996; Threlfall, 2005; Gadakh and Akhare, 2008; Alagar *et al.*, 2016; Rautela *et al.*, 2018). Moreover, fetal death at a very early age before the ossification process will lead to the absorption of entire fetal contents without forming a mummy. Unlike fetal mummification, fetal maceration differs by its putrified fetal contents in the uterine cavity under the presence of bacteria and oxygen.



Figure 1: **A.** The haematic mummified fetus of cattle expelled at term. **B.** The papyraceous mummified fetus of cattle. **C.** Four-month-old haematic mummified buffalo fetus. **D.** Stillbirth normal fetus and mummified fetus of goat removed at term. **E.** Haematic mummified twin fetus aborted in goat. **F.** The haematic mummified fetus of sheep. **G.** Eight variable-sized mummified fetuses and two stillbirth normal fetuses removed by caesarian section in the dog (Adapted from Vikram *et al.*, 2015)

Diagnosis

The mummification is usually not suspected until after the normal gestation period when calving fails to occur. No systemic or other types of illnesses are evident in cows and buffaloes except for spontaneous abortion in a few cases. In small ruminants, the mummified fetuses are spontaneously aborted or found along with the normal fetuses at the time of parturition (Fig. 1D, 1E & 1F). This condition in cows and buffaloes can be detected during regular pregnancy diagnosis or sometimes when animals have a history of prolonged anestrus. The primiparous cows and

buffaloes with a history of regression of formerly well-developing udder may be conjectured for fetal mummification. Transrectal palpation reveals no fluid ballottement in the uterus, usually felt like a tightly wrapped sac around a small firm fetus having a bird-like head. The empty sunken eye sockets are readily felt by transrectal palpation (Purohit and Gaur, 2011). As the process of fetal mummification continues, the uterine wall shrinks and tightly encompasses the formed mummy. The duration inside the uterus defines the appearance of the mummy, with more duration the drier, firm, and more leathery the fetus appears. The longer the duration the thicker the uterine wall and the animal exhibit anestrus due to the presence of progesterone by PCL. Sonographically uterine walls will be thickened, no anechoic fluid, no fetal heartbeat, rather echogenic areas, and hyperechoic bones will be seen (Dutt *et al.*, 2018). On a few occasions, the chronic mummified fetus gets lodged in the uterine wall. Rarely mummified fetus may reach the perimetrium of the uterus. In small ruminants, the characteristics of placental lesions and subsequent isolation of the infectious agents such as *C. burnetii*, *C. abortus*, and *T. gondii* is necessary for definitive diagnosis (Lefebvre, 2015). The mummified fetus is most often delivered along with the normal fetuses or retained inside the uterine cavity which can be visualized by sonography. In swine, mummified fetuses count concerning litter size, and the age of mummies are reliable indicators of the potential etiologic agent (Lefebvre, 2015). In an unvaccinated primiparous sow herd, when litters are small and multiple mummies are observed it should be suspected for PPV infection. The feed should be checked for fungal toxins when all the mummies are of the same size. The PRRSV infection is usually suspected when large mummified fetuses occur late in pregnancy (after day 70 of gestation) (Lefebvre, 2015). In addition to clinical history, serology appears to yield promising results for reliable diagnosis of PPV and PRRSV in the infected herd. In horses similar to cattle, transrectal palpation is a reliable technique, and while sonography exhibits hyperechoic bony structure devoid of anechoic fluids in the uterine lumen (Threlfall, 2005). In bitches, CHV infection is suspected from clinical history (vaccination status) and kennel status (Lefebvre, 2015). The sonography can be used in bitches for the diagnosis of early congenital anomalies of a fetus or mummified fetus (Khatti *et al.*, 2017). The clinical examination of pathologic changes seen in affected and mummified puppies delivered normally or by caesarian section are helpful (Fig. G) (Vikram *et al.*, 2015). The diagnosis in cats is difficult and extrauterine mummies found in the abdominal cavity or thoracic cavity as ossified mass are found accidentally by sonography or radiography or during abdominal surgery (Planellas *et al.*, 2012; Ivanova *et al.*, 2019).

Treatment and Control

In cow and buffaloes, post-diagnosis treatment of fetal mummification is quite simple. The decision tree for the diagnosis and treatment of fetal mummification in cows and buffaloes is frequently followed (Fig. 2) (Lefebvre *et al.*, 2009). The drugs that cause lysis of corpus luteum such as estrogens 80 mg stilbestrol or 5 mg estradiol 17 β and prostaglandins (PGs) (natural: 25mg or synthetic: 0.5mg intramuscularly) will help in expulsion of the mummified fetuses within 48 - 72 hours in cattle and buffaloes (Roberts, 1986; Purohit *et al.*, 2012). In about 80% of cases a single dose of estrogen or prostaglandin is sufficient, if not, a similar dose may be administered a second time. The clinicians must review and re-examine animals after 48-72 hours of treatment, as in some cases, the fetus may be lodged in the cervical canal or vaginal cavity (Jalakas, 2000). In such conditions, the vaginal tract requires much lubrication before gradual traction with a snare or Knowles cervical forceps to help remove the fetus or episiotomy may be performed. In chronic cases, one or several medical therapies such as prostaglandins (PGF_{2 α} , intramuscularly and PGE₂, locally on or in the cervix or intravenously), valethamate bromide, dexamethasone, estrogens, ritodrine or isoxsuprine HCl, may dilate the cervix, but usually fail to deliver the fetus which is tightly lodged to the uterine wall and animal continue to exhibit anestrus (Lefebvre *et al.*, 2009). In such cases, the mummy may be removed surgically through laparotomy followed by hysterotomy under paravertebral nerve block, if the uterine horns are suspended in the abdominal cavity ahead of the pelvic brim (Mahesh *et al.*, 2014). The small mummies are usually removed by the hysterotomy by a colpotomy in valuable cows (Hisbrunner *et al.*, 2004). Besides, the uterine lavage is indicated to remove debris from the uterine cavity. The medical removal of a mummified fetus will not affect future fertility, as the fetal contents and uterine cavity will be sterile. However, the surgical removal of a deeply embedded mummified fetus that is lodged against the uterine wall may affect fertility. In small ruminants, the mummified fetus is normally delivered at the time of kidding. If a fetus or fetuses are retained it is removed by vaginal delivery after lubrication (Chauhan *et al.*, 2014) or surgically through laparotomy. The *Coxiella* infection or border disease in small ruminants cannot be successfully treated. However, the incidence of *C. abortus* caused abortions in the last trimester can be reduced by treating with the tetracycline or decoquinat treatment. The *T. gondii* infection induced abortions may be reduced by the supplementation of monensin throughout the gestation. In the horse, the presence of CL indicates PGF_{2 α} (natural: 25 mg IM) as the drug of choice. In the absence of a CL, the cervix is relaxed to expel the mummified fetus by 17 β -estradiol (5 mg IM) or PGE₁ (200 μ g misoprostol)

administered locally on or in the cervix 24 hours before oxytocin is administered (Lefebvre, 2015). In some instances, the cervix is dilated manually using obstetrical instruments, and the mummy is delivered by manual traction of or by cesarean section. In swine, the best treatment is prevention. In dogs, no effective treatment is available. However, the mummied fetuses if present are delivered normally at the time of whelping or removed by the caesarian section (Vikram *et al.*, 2015). The current treatment protocols in cats are removal of mummies from the abdominal or thoracic cavity by surgical approach.

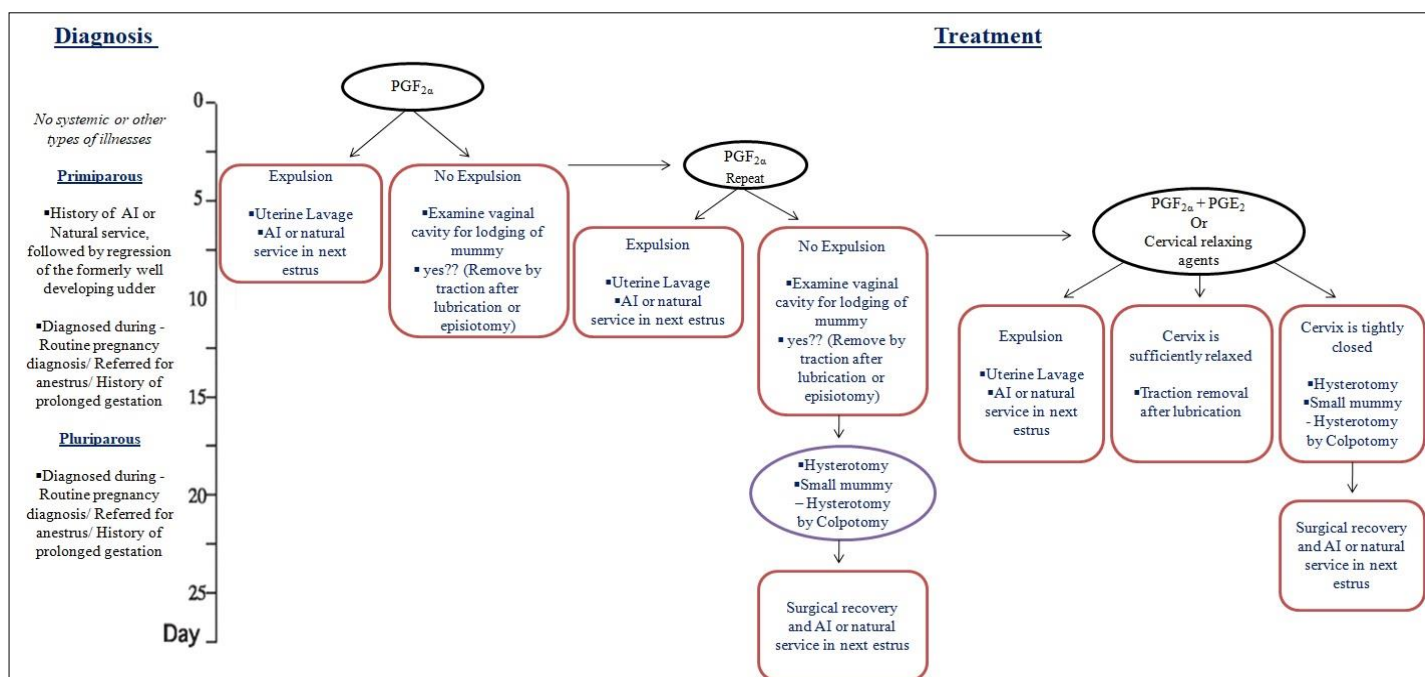


Figure 2: Modified decision tree for aiding in diagnosis and treatment of mummification in cows and buffaloes (Source: Adapted from Lefebvre *et al.*, 2009 with slight modification). Abbreviations: AI, artificial insemination; PGF_{2a}, prostaglandin F_{2a}; PGE₂, prostaglandin E₂

As the fetal mummification has no specific causes, the key is to maintain strict hygienic and good sanitary conditions and adopt the correct vaccination program. The emphasis should be given on the reproductive monitoring programmes. In sheep and goats, culling the animals which previously aborted is recommended. The new animals purchased should be quarantined to check *Coxiella* infection. The *C. abortus* is prevented by vaccination and animals should be fed in a feeding trough but not on the ground (Lefebvre, 2015). In swine, proper care in the form of optimal nutrition, stress management, rigorous sanitary protocols, and vaccination against PPV and PRRSV are all of the utmost importance (Lefebvre, 2015). In the horse, close monitoring to determine the double ovulation and confirmation of twin pregnancy as early as day 14 is recommended. This allows for early twin embryo reduction sonographically and the risk of fetal mummification will be minimized (Raggio *et al.*, 2008). In dogs, eradication of CHV from kennels and segregation infected animals is often unfeasible. The usage of artificial insemination, CHV free males, and maintaining good kennel biosecurity have been proposed as a way of minimizing CHV spread in dogs (Ronse *et al.*, 2005). In cats, maintenance of good sanitary conditions, reproductive monitoring programmes, and periodical vaccination against viral diseases are essential.

Conclusion

The fetal mummification is different in monotocous and polytocous species as the causative agents, clinical signs exhibited, treatment protocols, and prevention and control methods are different. A systematic study is necessary for different domestic animals to establish the exact etiology and to improve the diagnosis of fetal mummification. At present, the usage of better preventive medicine (vaccination), good nutritional care, effective stress management, and reproductive monitoring help to decrease the disease incidence and preserve the overall fertility of the herd.

Acknowledgments

The authors express their sincere gratitude to all the field veterinarians for their contribution and a great help in the preparation of this manuscript.

Conflict of Interests

There is no conflict of interest.

Publisher Disclaimer

IJLR remains neutral concerning jurisdictional claims in published institutional affiliation.

References

1. Alagar, S., Prakash, S., Selvaraju, M., Ravikumar, K., & Manokaran, S. (2016). Papyraceous mummification leading to dystocia of a normal fetus in a Mecheri ewe. *The Indian Journal of Animal Reproduction*, 38(1).
2. Arthur, G. H., Noakes, D. E., Pearson, H. & Parkinson, T.J. (1996). Infertility in the sow and gilt. *Text book of Veterinary Reproduction and Obstetrics*. London: WB Saunders.
3. Barth, A. D. (1986). Induced abortion in cattle. *Current therapy in Theriogenology*. Philadelphia, Pennsylvania, USA: WB Saunders.
4. Borges, V. F., Bernardi, M. L., Bortolozzo, F. P., & Wentz, I. (2005). Risk factors for stillbirth and foetal mummification in four Brazilian swine herds. *Preventive veterinary medicine*, 70(3-4), 165-176.
5. Broaddus, C. C., Lamm, C. G., Kapil, S., Dawson, L., & Holyoak, G. R. (2009). Bovine viral diarrhoea virus abortion in goats housed with persistently infected cattle. *Veterinary Pathology*, 46(1), 45-53.
6. Chauhan, P., Kapadiya, P., Sutaria, T., Nakhshi, H., & Sharma, V. (2014). Retention of mummified fetus due to uterine inertia after kidding in doe. *Veterinary Clinical Science*, 2(4), 64-66.
7. Drost, M. (2007). Complications during gestation in the cow. *Theriogenology*, 68(3), 487-491.
8. Dubey, J. P. (2009). Toxoplasmosis in sheep—the last 20 years. *Veterinary parasitology*, 163(1-2), 1-14.
9. Dutt, R., Dalal, J., Singh, G., & Gahalot, S. C. (2018). Management of fetal mummification/maceration through left flank caesarean section in cows—study of four cases. *Adv. Anim. Vet. Sci*, 6(1), 12-16.
10. Elmore, R. G. (1992). Focus on bovine reproductive disorders: managing cases of fetal mummification. *Veterinary medicine (USA)*.
11. Gadakh, A. K., & Akhare, S. B. (2008). Papyraceous mummified foetus in a crossbred cow. *Royal Veterinary Journal of India*, 4(1).
12. Hashimoto, A., Hirai, K., Yamaguchi, T., & Fujimoto, Y. (1982). Experimental transplacental infection of pregnant dogs with canine herpesvirus. *American journal of veterinary research*, 43(5), 844.
13. Ivanova, M., Ivanova, C., Marinkov, T., & Georgiev, P. (2019). Two cases of ectopic abdominal pregnancy in queens. *Tradition and Modernity in Veterinary Medicine*, 4(2), 21-25.
14. Jalakas, M. (2000). Mummification of fetal membranes in the bovine vagina: a case report. *Theriogenology*, 54(8), 1281-1284.
15. Khatti, A., Jena, D., Singh, S. K., Mondal, T., & Singh, S. V. (2017). Application of Ultrasonography in Canine Pregnancy—An Overview. *International Journal of Livestock Research*, 7(2), 20-27.
16. Le Cozler, Y., Guyomarc'h, C., Pichodo, X., Quinio, P. Y., & Pellois, H. (2002). Factors associated with stillborn and mummified piglets in high-prolific sows. *Animal Research*, 51(3), 261-268.
17. Lefebvre, R. C., Saint-Hilaire, É., Morin, I., Couto, G. B., Francoz, D., & Babkine, M. (2009). Retrospective case study of fetal mummification in cows that did not respond to prostaglandin F2 α treatment. *The Canadian Veterinary Journal*, 50(1), 71.
18. Lefebvre, R. C. (2015). Fetal mummification in the major domestic species: current perspectives on causes and management. *Veterinary Medicine: Research and Reports*, 6, 233.
19. Luedke, A. J. (1985). Effect of bluetongue virus on reproduction in sheep and cattle. *Progress in clinical and biological research*, 178, 71.
20. Mahesh, R., Prasad, V. D., Sumiran, N., & Devarathnam, J. (2014). Surgical management of mummified fetus in a cow. *International Journal of Livestock Research*, 4(4), 51-54.

21. Martucciello, A., De Mía, G. M., Giammarioli, M., De Donato, I., Iovane, G., & Galiero, G. (2009). Detection of Bovine viral diarrhoea virus from three water buffalo fetuses (*Bubalus bubalis*) in southern Italy. *Journal of veterinary diagnostic investigation*, 21(1), 137-140.
22. Modi, L. C., Patel, P. A., Patel, S. P., Patel, G. G., Joshi, A. H., & Suthar, D. N. (2011). Prevalence of reproductive problems in buffalo in Mehsana milk-shed area of Gujarat. *IJAVMS*, 5(4), 424-428.
23. Pizzigatti, D., Batista, F. A., Martins, C. F., Müller, T. R., & Hussni, C. A. (2012). Haematic mummification in a mare with twin pregnancy. *Journal of Equine Veterinary Science*, 32(5), 305-308.
24. Planellas, M., Martin, N., Pons, C., Font, J., & Cairo, J. (2012). Mummified fetus in the thoracic cavity of a domestic short-haired cat. *Topics in companion animal medicine*, 27(1), 36-37.
25. Purohit, G. N., & Gaur, M. (2011). Etiology, antenatal diagnosis and therapy of fetal complications of gestation in large and small domestic ruminants. *Theriogenology Insight-An International Journal of Reproduction in all Animals*, 1(1), 43-62.
26. Purohit, G. N., Kumar, P., Solanki, K., Shekher, C., & Yadav, S. P. (2012). Perspectives of fetal dystocia in cattle and buffalo. *Veterinary Science Development*, 2(1), e8-e8.
27. Raggio, I., Lefebvre, R. C., Poitras, P., Vaillancourt, D., & Goff, A. K. (2008). Twin pregnancy experimental model for transvaginal ultrasound-guided twin reduction in mares. *The Canadian Veterinary Journal*, 49(11), 1093.
28. Rautela, R., Kavya, K. M., Katiyar, R., Kumar, P. R., Jena, D., Khatti, A., & Das, G. K. (2018). Mummification of Triplets in a Doe. *Theriogenology Insight-An International Journal of Reproduction in all Animals*, 8(3), 111-113.
29. Roberts, S. J. (1986). *Veterinary Obstetric and Genital Diseases*. Woodstock, Vermont, USA: Selbstverl.
30. Ronsse, V., Verstegen, J., Thiry, E., Onclin, K., Aeberlé, C., Brunet, S., & Poulet, H. (2005). Canine herpesvirus-1 (CHV-1): clinical, serological and virological patterns in breeding colonies. *Theriogenology*, 64(1), 61-74.
31. Smith, M. C. (1979). Fetal mummification in a goat due to Japanese pieris (*Pieris japonica*) poisoning. *The Cornell veterinarian*, 69(1), 85-87.
32. Tengelsen, L. A., Yamini, B., Mullaney, T. P., Bell, T. G., Render, J. A., Patterson, J. S., ... & Ramos-Vara, J. A. (1997). A 12-year retrospective study of equine abortion in Michigan. *Journal of Veterinary Diagnostic Investigation*, 9(3), 303-306.
33. Threlfall, W. R. (2005). Singleton mummified fetus in a Standardbred mare. *Equine Veterinary Education*, 17(5), 235-239.
34. Vikram, R., Chaudhary, G. R., Sivanarayanan, T. B., Sushobhit, S., & Narayanan, K. (2015). Successful treatment of fetal mummification in a bitch by caesarean section: a case report. *Theriogenology Insight-An International Journal of Reproduction in all Animals*, 5(2), 147-151.
