



## Short Communication

### Effect of *Morinda Citrifolia* Fruit Juice and *Lactobacillus acidophilus* on Broiler Duodenal Morphology

Jai Sunder<sup>1\*</sup>, Sujatha Tamilvanan<sup>1</sup>, Pazhanivel Natesan<sup>2</sup>, Anandamoy Kundu<sup>1</sup>, Madhu Sudhan Kundu<sup>1</sup>

<sup>1</sup>Division of Animal Science, Central Agricultural Research Institute, Port Blair, A & N Islands– 744 101, India, Phone: 03192–250436, Fax: 03192–251068; <sup>2</sup>Department of Pathology, Madras Veterinary College, TANUVAS, Chennai

\*Corresponding author: jaisunder@rediffmail.com

#### ARTICLE HISTORY

Received: 2014–01–23  
Revised: 2014–02–16  
Accepted: 2014–02–20

**Key Words:** *Lactobacillus acidophilus*, *Morinda citrifolia*, Broilers, Duodenum, Histomorphological changes

#### ABSTRACT

The use of probiotics and medicinal plants has been studied by several workers as feed supplements for improvement of production and immunity in poultry. In the present study, *Morinda citrifolia* (noni) and *Lactobacillus acidophilus* (LAB) were evaluated to see the histomorphological changes observed in the duodenal villi in broiler birds. Commercial broiler chick (Ven – cob) were fed with noni and LAB alone and in combination. The section of the duodenum were cut and studied for histological analysis. Histological examinations revealed significant microscopical changes in crypt depth and villi height at the level of duodenum. The villi height and crypt depth varied significantly and were better with treatment groups than the control group. The intestinal mucous villi and crypt depth of lactobacillus fed broilers were of significantly very high approximately 439.64  $\mu$  and 51.39  $\mu$  respectively with the base having ridges. *Lactobacillus* significantly improved the intestinal mucous villi and crypt depth followed by noni at the duodenal morphology which is the primary site for the development of immune response and where nutrient uptake takes place. The results based on histological indexes of the intestinal mucosa indicated that the supplementation of *Morinda* juice improved the function of gut through its beneficial effects.

All copyrights reserved to Nexus® academic publishers

**ARTICLE CITATION:** Sunder J, Sujatha T, Pazhanivel N, Kundu A and Kundu MS (2014). Effect of *morinda citrifolia* fruit juice and *lactobacillus acidophilus* on broiler duodenal morphology. *Adv. Anim. Vet. Sci.* 2 (3S): 28 – 30.

In the last decade or so, probiotics have often been proposed as an alternative to antibiotics. The use of lactic acid bacteria as probiotic and feed supplements has been well studied to maximise production performance and immune response in livestock and poultry feed (Ibrahim et al. 2005; Salarmoini and Fooladi, 2011; Ghavidel et al. 2011). Further, the medicinal plant extracts in poultry as alternative to antibiotics for growth and immunity has been reported (Narimani–Rad et al. 2011; Javed et al. 2006; Mishra et al. 2008, Sunder et al. 2011). *Morinda citrifolia* commonly known as Noni has a rich history in Ayurveda and is present widely distributed throughout the coastal regions of many countries including India including the coastal area of Andaman & Nicobar group of Islands. The fruit and leaves of the plants are consumed as traditional foods in Southeast Asia and in the Pacific islands (West, 2006). The fruits of the plant have been recommended as a feed supplement for poultry to boost the growth performance and immunity (Sunder et al. 2011). However, the basic information on changes at duodenal wall structure that *Morinda citrifolia* brings to improve the feed utilization for maximum performance in poultry and its synergistic effect with the lactobacillus is not very well known. The intestinal epithelium acts as a natural barrier against pathogenic bacteria and toxic substances that are present in the

intestinal lumen. Absorption is totally dependent on the mechanisms that occur in the intestinal mucosa. Moreover, probiotics have been used to improve performance and consequently, the energetic efficiency of the intestine (Dobrogosz et al. 1991; Bradley et al. 1994; Spring, 1996; Savage et al. 1996; Hofacre et al. 2003; Pelicano et al. 2004). Hence, the present study was designed to study the influence of feeding of *Morinda citrifolia* fruit juice (noni) and *Lactobacillus acidophilus* (LAB) and their combination on duodenal morphology in commercial broilers.

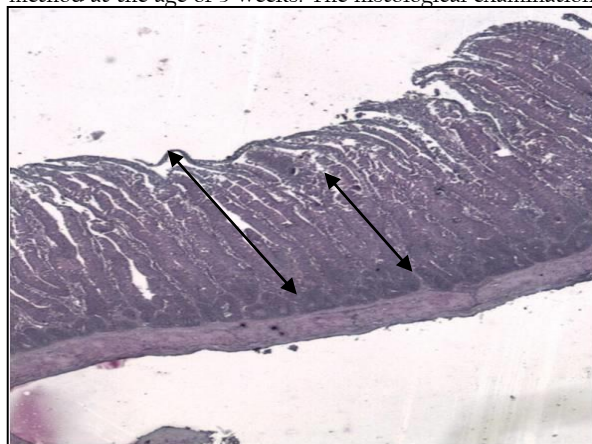
The *Morinda citrifolia* L. ripened fruits were collected, washed with clean water, dried and packed in polythene bags for preparation of the fresh juice. The concentrated juice was extracted from the Noni fruits and kept at room temperature for further use. *Lactobacillus acidophilus* NCDC–11 procured from NDRI, Karnal was used for the present study. The lactobacillus was grown in the Lactobacillus MRS agar (deMan Rogosa Sharpe) and biochemical test and sugar fermentation test were carried out to check the purity of the culture. The culture was maintained in MRS broth and used for further study.

A total of 124, day old commercial broiler chicks were randomly divided into four groups in completely randomized design with three replicates of 12 birds in each

replicate. Chicks were vaccinated for Ranikhet disease and Marek's disease at the hatchery. The experiment was conducted for 49 days. The birds were kept under deep litter system of rearing and provided with standard starter and finisher ration and water *ad-lib*. No medication, deworming was given throughout the experiment. The starter feed was given to the birds till 3<sup>rd</sup> week of age and then finisher feed was given to the birds from 4–7<sup>th</sup> week. Broilers were assigned to each of four treatment groups.

The diets were isoenergetic (3090 / 3150 ME Kcal /kg) and isonitrogenous (21.5 / 17.7 per cent crude protein) and formulated to meet the minimum nutrient requirements of broilers.

Six birds from each group were slaughtered by humane method at the age of 3 weeks. The histological examination

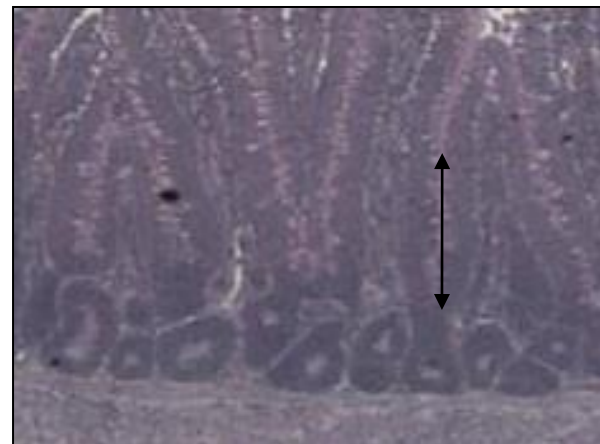


A

of intestinal wall was made by covering the stages of sampling, washing, inclusion, cutting and coloring with hematoxyline–eosine respectively and Mallory trichromic coloration was done according to the method described by Bancroft and Marilyn (2008).

Statistical analysis of measurements was carried as per Snedecor and Cochran (1994). The significance of the difference among the groups was determined by Duncan's multiple range tests (Petrie and Watson, 1991).

Histomorphometry of duodenal section is presented in table 1. Significant microscopical changes have taken place in crypt depth and villi height at the level of duodenum in layers of the intestinal wall (Figure 1).



B

Figure 1: Villi height and crypt depth of the duodenum of broiler fed with diet containing noni+LAB (a) control (b)

Table 1: Duodenal morphometry as influenced by LAB and noni groups

Intestinal indices	T <sub>1</sub> <i>Morinda citrifolia</i> juice (Noni)	T <sub>2</sub> <i>Lactobacillus acidophilus</i> (LAB)	T <sub>3</sub> (Noni+LAB)	T <sub>4</sub> (Control)
Crypt depth (µm)	52.42 <sup>a</sup> ± 2.23	51.39 <sup>a</sup> ± 1.98	51.07 <sup>a</sup> ± 2.20	43.60 <sup>b</sup> ± 1.36
Villi Length (µm)	357.98 <sup>ab</sup> ± 32.37	439.64 <sup>a</sup> ± 29.79	390.63 <sup>ab</sup> ± 18.78	323.75 <sup>b</sup> ± 12.49

The villi height and crypt depth varied significantly and were better with treatment groups than the control group. The control group mucosa contained villi with a medium height of approximately 323.75 µ that was statistically comparable with noni and noni + lactobacillus groups. The crypt depth (43.60 µ) of control group was significantly lowest. Intestinal glands attached to the villi consisted of a small lumen and epithelium as well as a small number of leukocytes. The birds from noni and noni+lactobacillus combination group had a villi of significantly medium height with comparatively better crypt depth as compared to control group. A large number of leukocytes were in transit. The intestinal mucous villi and crypt depth of lactobacillus fed broilers were of significantly very high approximately 439.64 µ and 51.39 µ respectively with the base having ridges. The capillary network underwent both hyperplasia and hypertrophy.

The significant efficacy of *Lactobacillus* followed by noni was evident at the duodenal morphology which is the primary site for the development of immune response and where nutrient uptake takes place. This improved

microscopic structure of villi by the *Morinda citrifolia* justified the data on better feed efficiency and overall growth performance as reported by Singh et al. (2008) who reported that *Morinda citrifolia* fruit rich in the nutraceutical compounds, amino acids, vitamins, minerals and coenzymes might have played an important role in uptake of the nutrients in the gut and in turn directly or indirectly help in metabolism of the nutrients. The finding of this work also justified the report of the positive influence of noni juice on immune response in poultry by Sunder et al. (2007 and 2011). Pelicano et al. (2003 and 2005) and Loddi et al. (2004) have found the beneficial effects of probiotics and prebiotics at 21 days of age on histological indexes of the intestinal mucosa as lower villi height in the duodenum of control birds compared with birds fed diets containing probiotics and prebiotics. This present work is agreed by the report of Lavinia et al. (2009) who provided the data regarding the changes in the microscopic structure of chicken duodenum and immune response as a consequence of aromatic plant extracted essential oils present in their feed. The findings of the present study corroborated the

finding of Adibmoradi et al. (2006) who reported that jejunal villus height was increased leading to increased villus height: crypt depth ratio in birds fed graded levels of garlic meal. It has been suggested that longer villi would result in an increased surface area and higher absorption of available nutrients (Casparly, 1992; Yasar and Forbes, 1999). Abdulkarim et al. (2013) also opined to the results of present study that villus height to crypt depth ratio in the jejunum was increased by feeding of phytogenic feed additive that might influence nutrient absorption and thus, improved feed conversion ratio. Herbal based poultry feed as a growth promoter modulated the gut function by increasing the duodenal villi height and crypt depth as found in the present study and that improved the body weight with marked improvement in digestibility of nutrients from supplementation of herbal growth promoter with equal competence as that of synthetic antibiotic (Kanduri et al. 2013). Further, the synergistic effect on duodenal villi height and crypt depth with herbal supplement and other proven growth promoters has also been reported by Hashemi et al. (2009) as it was very much evident by *Morinda* juice and probiotic groups in the present study.

In the present work, the histological changes that were brought in this experiment by *Morinda citrifolia* provided new information regarding the potential for using noni in human being as booster of immunity. The presence of several bioactive compounds in the *Morinda citrifolia* which might have enhanced the villi height and crypt depth. Further, an attempt to use the *Morinda* juice in chicken feed as an alternative to antibiotics has explored avenue with scientific evidence. Moreover, the simplified procedure of *Morinda* juice preparation instead of cumbersome other procedures involving in preparation of herbal extracts or essential oils has identified *Morinda* juice as a suitable immune enhancer for commercial broilers and it is a boon to these island small scale broiler producers who need not dependant on synthetic antibiotics that in turn shoot up the production cost of broilers. The abundance of these fruits in these islands is an added advantage for the Islands poultry farmers.

In conclusion, results indicated that the supplementation of *Morinda citrifolia* juice (noni) and *Lactobacillus acidophilus* improved the function of gut through its beneficial effects on histological indexes of the intestinal mucosa.

#### ACKNOWLEDGMENTS

The authors would like to thanks Director, CARI for providing financial assistance to carry out this work.

#### REFERENCES

Abdulkarim A, Amad, Wendler KR and Zentek J (2013). Effects of a phytogenic feed additive on growth performance, selected blood criteria and jejunal morphology in broiler chickens. *Emir. J. Food and Agri.* 25: 549–554.

Adibmoradi MB, Navidshad J, Seifdavati and Royan M (2006). Effect of dietary garlic meal on histological structure of small intestinal in broiler chickens. *J. Poultry Sci.* 43: 378–383.

Bancroft JD and Marilyn G (2008). *Theory and practice of histological techniques*. Sixth edition.

Bradley GL, Savage TF and Timm KI (1994). The effects of supplementing diets with *Saccharomyces cerevisiae* var. *boulardii* on male poultry performance and ileal morphology. *Poult. Sci.* 73:1766–1770.

Casparly WF (1992). Physiology and pathophysiology of intestinal absorption. *Ameri. J. Clin. Nutri.* 55:299S–308S.

Dobrosgz WJ, Black BL and Casas IA (1991). Delivery of viable *Lactobacillus reuteri* to the gastrointestinal tract of poultry. *Poult. Sci.* 70:158–168.

Ghavidel SZ, Adl KN, Sis NM, Aharizad S, Aghsaghali AM, Mohammadian M and Siadati SA (2011). Effects of lactobacillus-based probiotic on growth performance, mortality rate and carcass yield in broiler chickens. *Anim. Biolo. Res.* 2: 325–331.

Hashemi SR, Zulkifli I, Hair-Bejo M, Loh TC and Davoodi H (2009). Morphological Changes of the Intestinal in Broiler Chickens Fed Herbal Plant and Acidifier. *Academia.edu*

Hofacre CL, Beacorn T, Collett S and Mathis G (2003). Using competitive exclusion, mannan-oligosaccharide and other intestinal products to control necrotic enteritis. *J. Appl. Poult. Res.* 12: 60–64.

Ibrahim KA, Mahmoud A and Elhalim H (2005). Comparison of the efficacies of commercial probiotics on growth performance, carcass characteristics and some plasma constituents of broiler chicks. *Suez Canal Vet. Medici. J.* 8: 1–18.

Javed M, Durrani FR, Hafeez A, Khan R and Ahmad I (2006). Extract of plant mixture on carcass quality of broiler chicks. *J. Agri. Biolo. Sci.* 1: 115–121.

Kanduri AB, Saxena MJ, Ravikanth K, Maini S and Kokane SS (2013). Effect of dietary replacement of antibiotic growth promoter with herbal growth promoter on performance of broiler poultry birds. *Int. J. Appl. Pharm. Sci. Bio Med. Sci.* 2: 12–15.

Lavinia S, Dumitrescu G, Drinceanu D, Stef D, Daniela M, Julean C, Tetileanu R, and Corcionivoschi N (2009). The effect of medicinal plants and plant extracted oils on broiler duodenum morphology and immunological profile. *Romani. Biotech.Lett.* 14: 4606–14.

Loddi MM, Moraes VMB, Nakaghi LSO, Tucci FM, Hannas MI and Arika JA (2004). Mannan oligosaccharide and organic acids on performance and intestinal morphometric characteristics of broiler chickens. In: *Proceedings of the 20th Annual Symposium; Supplement I: p.45*

Mishra KP, Chanda S, Karan D, Ganju and Sawhney RC (2008). Effect of Sea-buckthorn (*Hippophae rhamnoides*) flavone on immune system: an in-vitro approach. *Phytotherapy Res.* 20: 3412 – 14.

Narimani M, Nobakht A, Aghdam H, Kamani J and Alireza L (2011). Influence of dietary supplemented medicinal plants mixture (Ziziphora, Oregano and Peppermint) on performance and carcass characterization of broiler chickens. *J. Medi. Plant Res.* 5: 5626–29.

Pelicano ERL, Souza PA, Souza HBA, Figueiredo DF, Boiogo MM, Carvalho SR, Bordon VF (2005) Intestinal Mucosa Development in Broiler Chickens Fed Natural Growth Promoters. *Brazi. J. Poult. Sci.* 7: 221–229.

Pelicano ERL, Souza PA, Souza HBA, Oba A, Leonel FR, Zeola NMBL and Boiogo MM (2004). Utilização de probióticos e/ou prebióticos como promotores de crescimento em raças iniciais de frangos de corte. *Revista Brasileira de Ciência Avícola Supplement* 6:17.

Pelicano ERL, Souza PA, Souza HBA, Oba A, Norkus EA, Kodawara LM and Lima TMA (2003). Morfometria e ultra-estrutura da mucosa intestinal de frangos de corte alimentados com dietas contendo diferentes probióticos. *Revista Portuguesa de Ciências Veterinárias* 98:124–134

Petrie A and Watson P (1991). *Statistics for Veterinary and Animal Sciences*. Blackwell Science Malden, MA.

Salarmoini M and Fooladi MH (2011). Efficacy of *Lactobacillus acidophilus* as Probiotic to Improve Broiler Chicks Performance. *J. Agri. Sci. Tech.* 13: 165–172.

Savage TF, Cotter PF and Zakrewska EI (1996). Effect of feeding a mannanoligosaccharide on immunoglobulin, plasma IgG and bile IgA of Wrolstad MW male turkey. *Poult. Sci.* 75 Supplement 1:143

Singh DR, Sunder J and Srivastava RC (2008). Peptide and mineral profile of *Morinda citrifolia* fruits and leaves. *International Journal of Noni Res.* 2: 72–78.

Snedecor GW and Cochran WG (1994). *Statistical Methods*. 9<sup>th</sup> ed. Oxford and IBH publishing Co., Calcutta

Spring P (1996). Effects of mannanoligosaccharide on different cecal parameters and on cecal concentrations of enteric pathogens in poultry. Dissertation (ETH no. 11897). ETH Zurich, Switzerland.

Sunder J, Rai RB, Yasmeen J, Kundu A and Jeyakumar S (2007). Immunomodulator effect of *Morinda citrifolia* in poultry. *Indian J. Anim. Sci.* 77: 1126–1128.

Sunder J, Kundu A, Singh DR, Jeyakumar S and Srivastava RC (2011). Effect of feeding of *Morinda citrifolia* fruit juice on growth, production and immune response in Nicobari fowl. *Indian J. Anim. Sci.* 81: 68–71.

West B (2006). A safety review of noni fruit juice. *J. Food Sci.* 71: 100–106.

Yasar S and Forbes JM (1999). Performance and gastrointestinal response of broiler chicks fed on cereal grain-based foods soaked in water. *Brit. Poult. Sci.* 40:65–76.