



## Dietary supplementation of *Cinnamomum verum* J. Presl and *Curcuma longa* L. extract on growth performance, antioxidant and metabolic enzymes activities in experimental rats

Sivaranjani R\*<sup>1</sup>, Leela NK<sup>1</sup>, Tejpal CS<sup>2</sup> & T John Zachariah<sup>1</sup>

<sup>1</sup>Department of Crop Production and Post Harvest Technology, ICAR-Indian Institute of Spices Research, Marikunnu (PO), Kozhikode-673 012, Kerala, India

<sup>2</sup>Department of Biochemistry and Nutrition, ICAR-Central Institute of Fisheries Technology, Matsyapuri (PO), Cochin-682 029, Kerala, India

Received 27 February 2018; revised 11 February 2019

*Cinnamomum verum* J. Presl and *Curcuma longa* L. have many biologically active metabolites, such as sterpenoids, phenolics with proven health benefits. The present study was undertaken to analyze the effect of cinnamon and turmeric extract on growth, blood parameters, and metabolic enzyme activities of albino Wistar rats. Methanol extract of cinnamon and turmeric mixture was supplemented in rat feed at 2.5 and 5% concentration, respectively and administered for 30 days. During the course of study, body weight, feed given, feed consumed data were collected at regular intervals. After the experimental period, animals were sacrificed, tissues separated, homogenized and assayed for the activity of catalase, superoxide dismutase (SOD), glutathione-s-transferase (GST), lactate dehydrogenase (LDH), malate dehydrogenase (MDH), alanine aminotransferase (AAT) and aspartate aminotransferase (AST). The results showed significant increase in liver catalase activity of treated animals and no significant changes in LDH, MDH, ALT and AST. No abnormalities were observed in the histopathology staining of tissue section. Overall, output of the present study could be useful for production of spices based antioxidant rich products for human health.

**Keywords:** Cinnamon, Culinary, Free radicals, Oxidative stress, Spice, Turmeric

Spices are the essence of Indian culinary preparations. They impart characteristic flavour, aroma and taste to our food. Apart from its culinary value, these spices are known to possess potential pharmacological properties against specific illness such as diabetes, cancer, cardio vascular disease, alzheimer's disease, etc. Spices like turmeric, ginger, cinnamon, clove, etc. are loaded with many phytochemicals *viz.* flavonoids, flavones, curcumin, catechins, quercetins, cinnamic acid, etc.<sup>1</sup>. They are not recognized as essential nutrients yet they either interact with dietary nutrients or act independently to exert health benefits as antioxidants, cardioprotective, anticancer, antiatherosclerosis, hepatoprotective and lipid lowering properties<sup>2-5</sup>. Saeed *et al.*<sup>5</sup> who studied phytochemistry of *Cinnamomum zeylanicum* have listed plethora of its beneficial properties, and recommend it as a dietary supplement and a natural feed additive instead of synthetic antibiotic growth promoters in poultry feed. In all the above mentioned diseases, the common

phenomenon is generation of free radicals and consequent tissue damage.

Free radicals are reactive oxygen and nitrogen molecules with unpaired electron in their outer shell orbit and are capable of reacting with major macro molecules and destabilizing them<sup>6</sup>. Apart from diseased state, free radicals such as superoxide anion, hydrogen peroxide, hydroxyl radical, peroxy, nitric oxide are unavoidable product of normal metabolic activities, and are also generated from external sources like cigarette smoking, industrial air pollutants, vehicle exhaust, radiation, pesticides and many other chemicals<sup>7</sup>. Human body has natural way of protecting cells from these radicals enzymatically by antioxidant enzymes like catalase, SOD and GPX and non-enzymatically by  $\alpha$ -tocopherol, ascorbic acid, reduced glutathione (GSH). When the production of free radicals exceed the removal rate, they readily react with lipid, protein and nucleic acid and destroy its architecture<sup>8</sup>. In such cases, dietary antioxidants helps in neutralizing these damaging radicals by accepting or donating the unpaired electron<sup>9</sup>. It is reported that healthy diets comprising antioxidants reduce the risk of

\*Correspondence:  
Phone: +91 495 2731410  
E-mail: ranjanigop@gamil.com

many lifestyle diseases associated with free radical tissue damage<sup>10,11</sup>.

Here, we investigated the effect of mixture of cinnamon and turmeric extract, commonly used as spice in Indian culinary, on antioxidant enzymes and few important metabolic enzymes in albino Wistar rats. The extract has given high antioxidant activity in *in vitro* assays which necessitated the *in vivo* study.

## Materials and Methods

### Sample preparation

Rhizomes of IISR Prabha variety of turmeric obtained from Experimental Farm, ICAR-IISR, Peruvannamuzhi and *Cinnamomum verum* bark collected from Plantation Corporation of Kerala Limited, chemmeni were used in this study. Coarsely ground turmeric rhizome and cinnamon bark samples were mixed in 1:2 ratio and extracted sequentially with hexane, chloroform and methanol in a soxhlet apparatus. The extracts were filtered and concentrated in a vacuum rotary evaporator with water bath temperature set at 60°C. The dried powdered extract was stored at 4°C until use. The total phenolic content of the extract was measured using Folin-ciocalteu reagent following Singleton & Rossi<sup>12</sup> method. *In vitro* total antioxidant activity of the extract is measured by its DPPH radical scavenging activity<sup>13</sup> and Ferric reducing power assay<sup>14</sup>.

### Experimental animals

Eighteen male Wistar rat weighing 150-230 g were selected and housed in an individual polypropylene cages placed in a well-ventilated laboratory with temperature of 25±2°C, relative humidity of 85% and an alternate 12 h dark/light cycles. Rats were allowed to acclimatize to the cage condition and given normal rat feed and water *ad libitum* for one week before the start of the experiment. The experimental protocol was carried out according to the guidelines of the Committee for the Purpose of Control and Supervision of Experiments on Animals (CPCSEA), New Delhi and approved by the Institutional Animal Ethics Committee of ICAR-Central Institute of Fisheries Technology, Cochin.

### Experimental diets and Treatment

Rats were divided into three groups namely Control, T1 and T2. Control group animals were given normal rat chow diet only. T1 group animals were given normal rat chow mixed with 2.5% of cinnamon and turmeric extract. T2 group animals were given

normal rat chow mixed with 5% of cinnamon and turmeric extract. The experimental procedure for *in vivo* studies was similar to that previously described method<sup>15</sup>. Methanol extract of cinnamon and turmeric mixture was incorporated at 2.5 and 5% concentration into powdered rat diet and made into pellet. Control diet was prepared by the same method to nullify the differences in loss of vitamin and mineral content as a result of the drying process. This diet was fed to animals for 30 days. At the end, animals were starved overnight and sacrificed under ether vapour. Blood, liver, kidney, heart and muscles were harvested, weights are noted down and are stored at -80°C until further analysis. The blood samples were used for hematological analysis on the same day.

### Growth performance parameters

The animals were weighed at the start and at every 7 days interval till 30 days. The growth performance was evaluated in terms of feed intake (FI), weight gain (%), specific growth rate (SGR) and feed efficiency ratio (FER).

weight gain (%) = (final weight - initial weight) / initial weight × 100

SGR = 100 (log<sub>e</sub> average final weight - log<sub>e</sub> average initial weight) / number of days

FER = weight gain (g) / feed intake (g)

### Preparation of tissue homogenate and serum collection

Frozen tissues (200 mg) were homogenized with 5% sucrose in a homogenizer and centrifuged at 10000 rpm for 10 min. The supernatant was collected and stored at -80°C for further analysis. The blood sample collected were kept at room temperature of 30±2°C till it clots and then centrifuged at 3500 rpm for 3 min to collect the serum. The collected serum was stored at -20°C for further analysis.

### Enzyme assays

Catalase (CAT) activity was assayed using Abei<sup>16</sup> method. The specific activity of it was expressed as μmoles of H<sub>2</sub>O<sub>2</sub> degraded/min/mg of protein. Superoxide dismutase (SOD) activity was measured based on Misra and Fridovich<sup>17</sup> method and the specific activity is expressed as units/mg protein. Glutathione-S-transferase (GST) activity was determined using Habig *et al.*<sup>18</sup> method with slight modification. GST enzyme activity is expressed as nmoles of CDNB conjugae formed/min/mg of protein. Lactate dehydrogenase (LDH) and malate dehydrogenase (MDH) was assayed using modified Shonk and Boxer<sup>19</sup> method, and specific activity was calculated and expressed as μmoles of NADH consumed/

min/mg of protein for LDH and  $\mu$ moles of NADH produced/min/mg of protein for MDH. Both ALT and AST activity was determined by following Wotten<sup>20</sup> method. The specific activity is expressed as nmoles of pyruvate formed/min/mg of protein. Estimation of protein content was done using Lowry *et al.*<sup>21</sup> method.

#### Histopathology

Formalin fixed tissue samples were embedded in a paraffin wax, cut into thin section using microtome and stained used heamatoxylin-eosin dye. The prepared slides were then analyzed for structural modifications induced by the treatments.

#### Statistical analysis

The data were analyzed using one way ANOVA and expressed as mean  $\pm$  SEM. The significant differences between means were determined using Duncan's multiple range comparison tests. The level of significance was set at 5%. All analyses were performed using statistical software package SPSS version 16.

### Results and Discussion

Biochemical analysis of the sequential extract revealed that methanol extract has the highest (373.43 $\pm$ 5.3) phenolics content followed by chloroform (295.3 $\pm$ 7.9) and hexane (228.9 $\pm$ 5). Likewise, methanol extract showed higher antioxidant activity as measured by DPPH radical scavenging assay and Ferric Reducing Power assay (Table 1). Based on the results, phenolics-rich and antioxidant rich methanol extract was selected for animal experiment (Table 1).

After 30 days of dietary supplementation, the average % weight gain in T1 is found to be the lowest (31.8%) whereas T2 showed 38.24% weight gain as compared to control which showed 38.17% weight gain. Yet, statistical analysis showed no significant ( $P > 0.05$ ) variation in weight gain % of treated and control animal. In a clinical study, Sfar *et al.*<sup>22</sup> provided the evidence that dietary supplementation of cinnamon leads to decreased BMI and waist circumference as

compared to control group of obese diabetic men. FER in control group was the highest (0.22) followed by T2 (0.17) and T1 (0.16) (Table 2). Since animals were maintained without stress treatment, the study may help in understanding the effect of spices extract on growth in normal environment.

Table 3 shows the organ weight of rats treated with cinnamon and turmeric extract. Only T2 showed significant increase ( $P > 0.05$ ) in the liver weight of rats compared to control. No significant difference ( $P > 0.05$ ) was observed in case of kidney and heart in treatment animals as compared to control. This is in conformity with earlier reports that flavonoid and phenolic rich compounds increase the liver weight<sup>23</sup>. However, some authors attribute this to glycogen deposition which could not be observed here in our study<sup>24,25</sup>. Histopathology of liver sections and analysis of enzyme activities like LDH, MDH, AST and ALT showed that despite increased liver weight, no abnormalities in the tissue section and enzyme activities were observed which shows that the extract

Table 2 — Effect of Cinnamon and turmeric extract on feed intake, weight gain percentage, specific growth rate and feed efficiency ratio (FER) of rats

Parameters	Control	T1	T2
Feed Intake (g)	391.3 $\pm$ 15.6	437.2 $\pm$ 17.7	433.4 $\pm$ 13.5
Total wt. gain (g)	81.3 $\pm$ 9.89	67.3 $\pm$ 6.64	72.6 $\pm$ 6.97
% wt. gain	38.17 $\pm$ 6.91	31.81 $\pm$ 5.6	38.24 $\pm$ 5.29
SGR	1.27 $\pm$ 0.16	1.08 $\pm$ 0.12	1.16 $\pm$ 0.13
FER	0.22 $\pm$ 0.0	0.16 $\pm$ 0.0	0.17 $\pm$ 0.0

[Values are expressed as mean  $\pm$  SE of six replication]

Table 3 — Organ weight of rats

Tissues	Treatment	Organ wt. (g)	Organ wt. ratio
Liver	Control	6.26 $\pm$ 0.4 <sup>a</sup>	2.44 $\pm$ 0.1 <sup>a</sup>
	T1 (2.5%)	6.85 $\pm$ 0.4 <sup>ab</sup>	2.79 $\pm$ 0.3 <sup>a</sup>
	T2 (5%)	7.5 $\pm$ 0.3 <sup>b</sup>	3 $\pm$ 0.0 <sup>a</sup>
Kidney	Control	1.5 $\pm$ 0.1 <sup>a</sup>	0.58 $\pm$ 0.0 <sup>a</sup>
	T1 (2.5%)	1.56 $\pm$ 0.2 <sup>a</sup>	0.63 $\pm$ 0.1 <sup>a</sup>
	T2 (5%)	1.57 $\pm$ 0.1 <sup>a</sup>	0.63 $\pm$ 0.0 <sup>a</sup>
Heart	Control	0.73 $\pm$ 0.0 <sup>a</sup>	0.28 $\pm$ 0.0 <sup>a</sup>
	T1 (2.5%)	0.7 $\pm$ 0.1 <sup>a</sup>	0.28 $\pm$ 0.0 <sup>a</sup>
	T2 (5%)	0.74 $\pm$ 0.0 <sup>a</sup>	0.3 $\pm$ 0.0 <sup>a</sup>

[Different superscript (<sup>a,b</sup>) in the row indicate significant difference ( $P < 0.05$ ) between treatments (control, T1 and T2). Values are expressed as mean  $\pm$  SE of six replications]

Table 1 — Total phenolics, DPPH radical scavenging activity and Ferric reducing activity of sequential extract of cinnamon and turmeric mixture

Solvent	Total phenolics (mg GAE/g)	DPPH radical scavenging activity (IC <sub>50</sub> $\mu$ g)	Ferric reducing power assay (Molar Ascorbic Acid Equivalents/g)
Hexane	228.9 $\pm$ 5.7	44.5 $\pm$ 1.8	0.79 $\pm$ 0.0
Chloroform	295.3 $\pm$ 7.9	37.2 $\pm$ 0.7	1.00 $\pm$ 0.0
Methanol	373.4 $\pm$ 5.3	7.4 $\pm$ 0.3	1.85 $\pm$ 0.2
BHA standard	-	5.4 $\pm$ 0.3	2.34 $\pm$ 0.1

[Values are expressed as mean  $\pm$  SE of two replication]

has no adverse effect on liver. Even though T2 showed significant increase in liver weight, the ratio of its organ weight to body weight showed no statistically significant increase (Table 3).

Analysis of haematological parameters and lipid profile of serum showed no significant variation in blood parameters of hemoglobin content, RBC count, platelet count, etc. of treated animals as compared to control (Table 4). In serum lipid profile, though T2 animals showed high cholesterol number in absolute value, their cholesterol to HDL ratio (0.25) which is recognized as the indicator of many heart related diseases<sup>26</sup> is on par with control (0.25).

#### Enzyme assays

Fig. 1 shows enzyme activities in different tissues of treated and control animals. Activities of different antioxidant enzymes are often considered as biomarker

Table 4 — Levels of hematological and serum lipid parameters in rats treated with cinnamon turmeric extract

Blood Parameters	Control	T1	T2
Total cell count (No.)	10850	12950	10500
Haemoglobin (g/dl)	15.5±1.27	14.3±0	13.5±0.57
RBC (million cells/mm <sup>3</sup> )	7.9±0.57	8±0.16	7.15±0.45
PCV (%)	42.75±3.8	39.95±0.04	37.9±1.39
MCV (%)	53.65±0.86	50.35±0.61	52.85±1.27
MCH (%)	18.95±0.20	17.95±0.20	18.75±0.37
MCHC (%)	35.4±0.16	35.75±0.04	35.55±0.20
Platelet count (lakh cells/mm <sup>3</sup> )	8.8±0.41	8.65±0.53	8.2±0.08
Serum lipid parameters			
cholesterol (mg/dl)	83±6.53	87.5±4.49	107±3.27
Triglycerides (mg/dl)	83±5.72	78.5±3.67	73.5±7.76
HDL (mg/dl)	21±1.63	21.5±0.41	27±0.82
LDL (mg/dl)	45±3.67	50±4.9	65±4.08
VLDL (mg/dl)	16.5±1.22	16±0.82	15±1.63
Cholesterol ratio	0.25	0.25	0.25

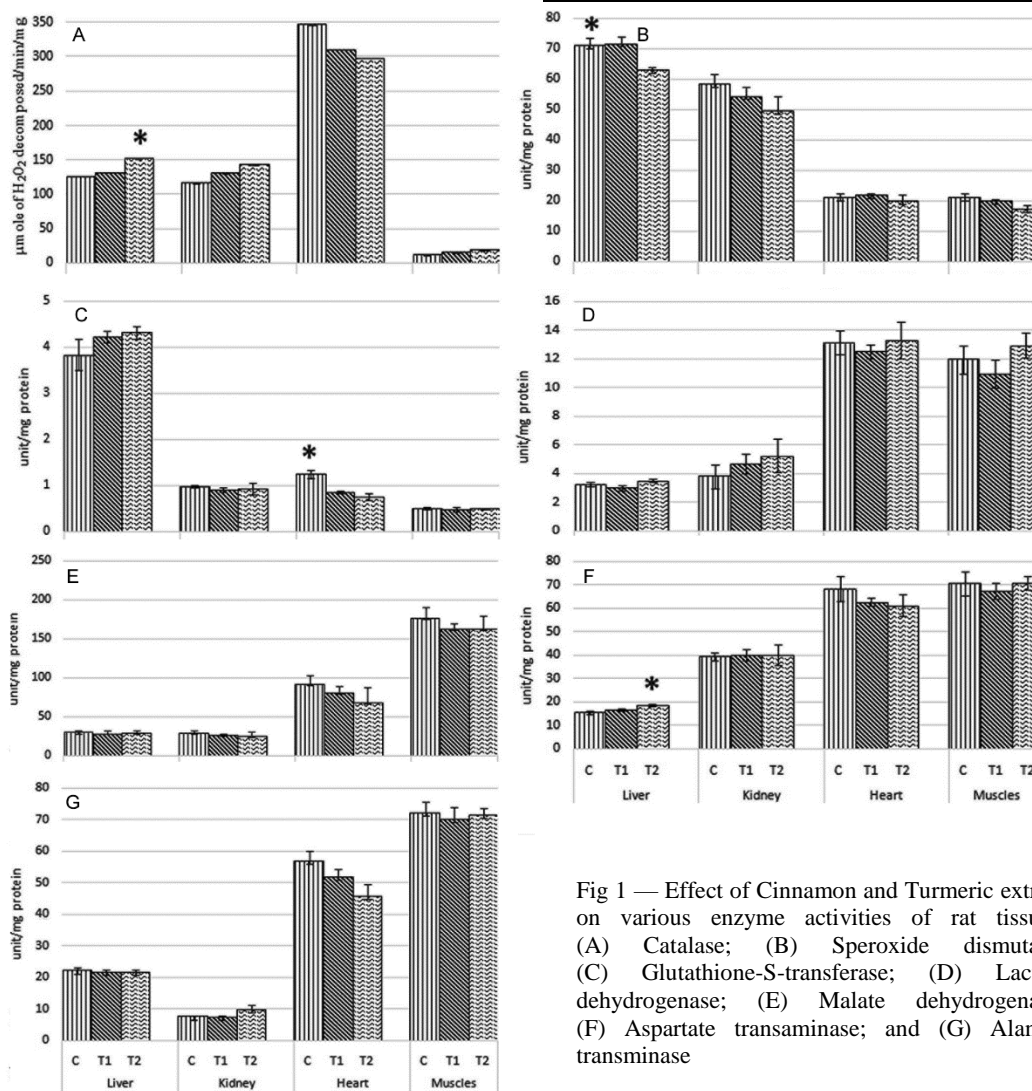


Fig 1 — Effect of Cinnamon and Turmeric extract on various enzyme activities of rat tissues. (A) Catalase; (B) Superoxide dismutase; (C) Glutathione-S-transferase; (D) Lactate dehydrogenase; (E) Malate dehydrogenase; (F) Aspartate transaminase; and (G) Alanine transaminase

for oxidative damage of tissues in animals. In our experiment, treatment group showed significantly ( $P > 0.05$ ) higher catalase activity in liver than control group. It could be due to induction/activation of catalase by polyphenols present in the extract<sup>27</sup>. Similar results have been reported in earlier studies using phenolic and flavonoid rich plant extracts<sup>28-31</sup>. Superoxide dismutase (SOD) catalyzes dismutation and neutralizes superoxide anion produced in the cell. In our results, T2 showed significant reduction ( $P > 0.05$ ) in SOD activity in liver and muscles as compared to control. It could be due to phenolics present in the extract that readily scavenge superoxide anion<sup>32</sup> because of the presence of numerous reactive hydroxyl group in the metabolites like cinnacassols, cinnzyelonol, several other benzyl isoquinoline alkaloids, flavanols and glucosides from cinnamon; and curcumin, demethoxy curcumin and bisdemethoxy curcumin and other diterpene, sesquiterpene compounds from turmeric<sup>33-35</sup>. This is in concurrence with the earlier studies of decreased SOD activity in spices extract treated animals with no adverse effect on physiology<sup>36,37</sup>. Another important antioxidant enzyme is GST which is involved in cellular drug metabolism and cellular stress responses<sup>38</sup>. It has been reported that xenobiotics influence GST activity in animal tissues to protect from oxidative damages induced by xenobiotics<sup>39</sup>.

Our result showed no significant change ( $P > 0.05$ ) in the activity of GST in liver, muscles and kidney. It could be interpreted that the phenolic rich cinnamon turmeric extract is not perceived as dangerous xenobiotics even as high as 5% concentration<sup>40</sup>.

LDH and MDH enzymes work together in the energy intensive respiratory pathway to keep the cellular metabolic flux at a normal rate. In our study, both their activity showed no significant ( $P > 0.05$ ) change in the treatment tissue as compared to control tissues. Increased LDH activity is an indicator of skeletal and myocardial tissue damage which is not observed in our study<sup>41,42</sup>. ALT and AST are metabolic enzymes with clinical and toxicological importance, and changes in their activities are indicative of tissue damage by any toxic chemical or diseases<sup>43</sup>. In our experiment, only in liver tissue treatment showed significant ( $P > 0.05$ ) increase in AST activity than control<sup>44</sup>. Remaining tissues showed no significant variation ( $P > 0.05$ ) from control. This signifies that treatment with spices extracts did not alter the carbon and nitrogen flux by modifying the activity of these enzymes.

#### Histopathology of tissues

Histopathological examination of tissue sections of heart, liver and kidney showed no abnormalities in treatment tissues (Fig. 2). Heart tissues of treated animals showed normal cardiac myocytes and there is no evidence

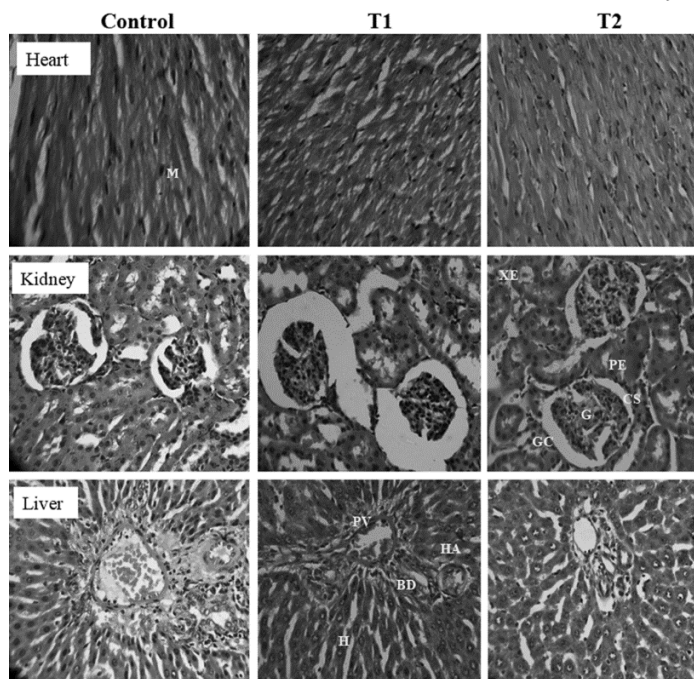


Fig. 2 — Histopathological examination of Heart, Kidney and Liver tissues of control and treatment animals. [M, Myocytes; G, Glomerulus; GC, Glomerular capsule; CS, Central Space; PE, Proximal epithelium; XE, Distal epithelium; PV, Portal vein; H, Hepatocytes; BD, Bile duct; and HA, Hepatic Artery]

of inflammation or myocardial scarring found in the section. In case of kidney, tissues from treatment animals showed no inflammation, no scarring and no epithelial damage. Cortex, medulla and glomeruli looked normal, tubular epithelium looked healthy and no abnormalities were found. In liver tissue, hepatocytes looked normal and no fatty changes, no inflammations were observed. Portal tracts also looked normal with no inflammation or fibrosis observed.

### Conclusion

The present study concludes that methanol extract of phenolic rich cinnamon and turmeric mixture showed higher *in vitro* antioxidant activity. Dietary supplementation of this extract influenced the growth parameters and did not alter the metabolism of animals as evidenced by the activities of LDH, MDH, ALT and AST enzymes. Such supplementation also maintained and enhanced the antioxidant enzyme activities like catalase in liver which are involved in combating oxidative stress. The extract did not cause any damage to cellular machinery as revealed by the histopathological examination of liver, kidney and heart where normal cellular architecture showed no pathological modifications. Since cinnamon and turmeric is loaded with numerous bioactive phytochemicals with nutraceutical applications, further study could be extended to elucidate the synergistic effect of cinnamon and turmeric to alleviate oxidative stress mediated diseases in disease induced animal models.

### Acknowledgement

Authors acknowledge ICAR for financial support, and thank Dr. Hemachandra, Pathologist, Ashwini Clinical Lab, Kozhikode, Kerala for interpretation of histopathological slides.

### Conflict of interest

Authors declare that they have no conflict of interests.

### References

- 1 Mehta SK & Gowder SJT, Members of Antioxidant Machinery and Their Functions. *Basic Principles and Clinical Significance of Oxidative Stress*, (Ed.: Gowder SJT, IntechOpen, London, UK), 2015. DOI: 10.5772/61884.
- 2 Rice-Evans C & Miller NJ, Antioxidant activities of flavonoids as bioactive components of food. *Biochem Soc Trans*, 24 (1996) 790.
- 3 Saravanan N, Patil MA, Udaykumar P, Suryanarayana P & Reddy GB, Dietary ginger improves glucose dysregulation in a long-term high-fat high-fructose fed prediabetic rat model. *Indian J Exp Biol*, 55 (2017) 142.
- 4 Aborehab NM & Boshra SA, Hepatoprotective effect of ginger and grape seed, alone and in combination orally, in paracetamol induced acute liver toxicity in rats. *Indian J Exp Biol*, 57 (2019) 274.
- 5 Saeed M, Kamboh A, Syed S, Babazadeh D, Suheryani I, Shah Q & Chao S, Phytochemistry and beneficial impacts of cinnamon (*Cinnamomum zeylanicum*) as a dietary supplement in poultry diets. *World Poultry Sci J*, 74 (2018) 331.
- 6 Halliwell B & Gutteridge JMC, Free radicals in Biology and Medicine. 4<sup>th</sup> edn. (Oxford University Press, London, UK), 2007.
- 7 De Groot H, Reactive oxygen species in tissue injury. *Hepato gastroenterology*, 41 (1994) 328.
- 8 Willcox JK, Ash SL & Catignani GL, Antioxidants and prevention of chronic disease. *Crit Rev Food Sci Nutr*, 44 (2004) 275.
- 9 Rice-Evans C, Miller NJ & Paganga G, Structure-antioxidant activity relationships of flavonoids and phenolic acids. *Free Radic Biol Med*, 20 (1996) 933.
- 10 Bahorun T, Soobrattee MA, Luximon-Ramma V & Aruoma OI, Free radicals and antioxidants in cardiovascular health and disease. *Internet J Med Update*, 1 (2006) 17.
- 11 Sharma S, Mishra V & Srivastava N, Protective effect of *Trigonella foenum-graecum* and *Cinnamomum zeylanicum* against diabetes induced oxidative DNA damage in rats. *Indian J Biochem Biophys*, 57 (2020) 15.
- 12 Singleton VL & Rossi JA, Colorimetry of total phenolics with phosphomolybdic-phosphotungstic acid reagents. *Am J Enol Vitic*, 16 (1965) 144.
- 13 Blois MS, Antioxidant determinations by the use of a stable free radical. *Nature*, 181 (1958) 1199.
- 14 Oyaizu M, Studies on product of browning reaction: antioxidative activities of products of browning reaction prepared from glucose amine. *Jpn J Nutr*, 44 (1986) 307.
- 15 Gray AM & Flatt PR, Pancreatic and extra-pancreatic effects of the traditional anti-diabetic plant, *Medicago sativa* (Lucerne). *Br J Nutr*, 78 (1997) 325.
- 16 Abei, H, Catalyse *in vitro*. *Methods enzymol*, 105 (1984) 121.
- 17 Misra HP & Fridovich I, The role of superoxide anion in the autooxidation of epinephrine and a simple assay for superoxide dismutase. *J Biol Chem*, 247 (1972) 3170.
- 18 Habig WH, Pabst MJ & Jacoby WB, Glutathione S-transferases: the first enzymatic step in mercapturic acid formation. *J Biol Chem*, 249 (1974) 7130.
- 19 Shonk CE & Boxer GE, Enzyme patterns in human tissues. I. Methods for the determination of glycolytic enzymes. *Cancer Res*, 24 (1964) 709.
- 20 Wooten IDP, Microanalysis in Medical Biochemistry, 4<sup>th</sup> edn. (J & A Churchill Ltd., London, UK), 1964.
- 21 Lowry OH, Rosebrough NJ, Farr AL & Randall RJ, Protein measurement with the Folin phenol reagent. *J Biol Chem*, 193 (1951) 265.
- 22 Sfar M, Hfaiedh BK, Ben-Mahrez K, Shkiri AH, Rayana BC, Chemli R, Mami BF & Slama BF, Effect of cinnamon supplementation on resistin and ghrelin in obese diabetic men. *Indian J Tradit Knowl*, 18 (2019) 694.
- 23 Ekenayanwul RC & Njoku OU, Acute and subacute oral toxicity study on the flavonoid rich fraction of *Monodora*

- tenuifolia* seed in albino rats. *Asian Pac J Trop Biomed*, 4 (2014) 194.
- 24 Kazeem MI, Akanji MA, Yakubu MT & Ashaga AOT, Protective Effect of Free and Bound Polyphenol Extracts from Ginger (*Zingiber officinale* Roscoe) on the Hepatic Antioxidant and Some Carbohydrate Metabolizing Enzymes of Streptozotocin-Induced Diabetic Rats. *Evid Based Complement Alternat Med*, (2013) doi:10.1155/2013/935486
- 25 Ferrer JC, Favre C, Gomis RR, Fernandez-Novell JM, Garcia-Rocha M, De la Iglesia N, Cid E & Guinovart JJ, Control of glycogen deposition. *FEBS Letters*, 546 (2003) 127.
- 26 Lemieux I, Lamarche B, Couillard C, Pascot A, Cantin B, Bergeron J, Dagenais RG & Despres J, Total Cholesterol/HDL Cholesterol Ratio vs LDL Cholesterol/HDL Cholesterol Ratio as Indices of Ischemic Heart Disease Risk in Men - The Quebec Cardiovascular Study. *Arch Intern Med*, 161 (2001) 2685.
- 27 Sindhu RK, Koo JR, Roberts CK & Vaziri ND, Dysregulation of hepatic superoxide dismutase, catalase and glutathione peroxidase in diabetes response to insulin and antioxidant therapies. *Clin Exp Hypertens*, 26 (2004) 43.
- 28 Nauman M, Kale RK, Dhruve P & Singh RP, Determination of antioxidant potential of *Salix aegyptiaca* L. through biochemical analysis. *Indian J Exp Biol*, 58 (2020) 198.
- 29 Adeyemi JA, Arowolo OK, Olawuyi ST, Alegbeleye D, Ogunleye A, Bamidele OS & Adedire CO, Effect of co-administration of Green Tea (*Camellia sinensis*) on Clove- (*Syzygium Aromaticum*) Induced Hepatotoxicity and Oxidative Stress in Wistar Rats. *Indian J Physiol Pharmacol*, 62 (2018) 195.
- 30 Shen SQ, Zhang Y, Xiang JJ & Xiong CL, Protective effect of curcumin against liver warm ischemia/reperfusion injury in rat model is associated with regulation of heat shock protein and antioxidant enzymes. *World J Gastroenterol*, 13 (2007) 1953.
- 31 Ganesan K, Jayachandran M & Xu B, A critical review on hepatoprotective effects of bioactive food components. *Crit Rev Food Sci Nutr*, 58 (2018) 1165.
- 32 Han X, Shen T & Lou H, Dietary Polyphenols and their Biological Significance. *Int J Mol Sci*, 8 (2007) 950.
- 33 Aruoma OI, Nutrition and health aspects of free radicals and antioxidants. *Food Chem*, 32 (1994) 671.
- 34 Leela NK, Cinnamon. *Chemistry of Spices*, (Eds.: Parthasarathy VA, Chempakam B & Zachariah J, (CAB International, Willingford, UK), 2008.
- 35 Dorri M, Hashemitabar S & Hosseinzadeh H, Cinnamon (*Cinnamomum zeylanicum*) as an antidote or a protective agent against natural or chemical toxicities: a review. *Drug Chem Toxicol*, 41 (2018) 338.
- 36 Otunola GA, Oloyede OB, Oladiji AT & Afolayan AJ, Selected spices and their combination modulate hypercholesterolemia- induced oxidative stress in experimental rats. *Biol Res*, 47 (2014) 5.
- 37 Asimi OA & Sahu NP, Effect of Antioxidant Rich Spices, Clove and Cardamom Extracts on the Metabolic Enzyme Activity of *Labeo rohita*. *J Fisheries Livest Prod*, 4 (2015) 157.
- 38 Hayes JD & Pulford DJ, The glutathione S-transferase supergene family: regulation of GST and the contribution of the isoenzymes to cancer chemoprotection and drug resistance. *Crit Rev Biochem Mol Biol*, 30 (1995) 445.
- 39 Hunaiti AA, A comparison of cardiac glutathione S-transferases from wild and domestic animals. *Comp Biochem Physiol B*, 95 (1990) 275.
- 40 Sharma UK, Kumar R, Ganguly R, Gupta A, Sharma AK & Pandey AK, Cinnamaldehyde, An active Component of Cinnamon provides Protection against Food colour induced Oxidative stress and Hepatotoxicity in albino Wistar rats. *Vegetos*, 31 (2018) 123.
- 41 Rosalki SB, Roberts R, Katus HA, Giannitsis E & Ladenson JH, Cardiac Biomarkers for Detection for Myocardial Infarction: Perspectives from past to present. *Clinic Chem*, 50 (2004) 2205.
- 42 Laterza OF, Modur VR & Ladenson JH, Biomarkers for Tissue injury. *Biomark Med*, 2 (2008) 81.
- 43 Giannini EG, Testa R & Savarino V, Liver enzyme alteration: a guide for clinicians. *Can Med Assoc J*, 172 (2005) 367.
- 44 Prokop J, Anzenbacher P, Mrkvicová E, Pavlata L, Zapletalová I, Štastník O, Martinek P, Kosina P & Anzenbacherová E, *In vivo* evaluation of effect of anthocyanin-rich wheat on rat liver microsomal drug-metabolizing cytochromes P450 and on biochemical and antioxidant parameters in rats. *Food Chem Toxicol*, 122 (2018) 225. <https://doi.org/10.1016/j.fct.2018.10.029>.