



International Journal of Fisheries and Aquatic Studies

ISSN: 2347-5129

IJFAS 2013; 1(2): 45-49

www.fisheriesjournal.com

Received: 27-11-2013

Accepted: 09-12-2013

Anita Bhatnagar

Department of Zoology, Kurukshetra
University, Kurukshetra-139 119,
Haryana, India.

Rajesh Dayal

National Bureau of Fish Genetic
Resources, Canal Ring Road, Teli
Bagh, Lucknow – 226 002, UP,
India.

Shipra Chowdhary

National Bureau of Fish Genetic
Resources, Canal Ring Road, Teli
Bagh, Lucknow – 226 002, UP,
India.

Wazir S. Lakra

Central Institute of Fisheries
Education, Panch Marg, Off Yari
Road, Mumbai, MS, India.

S. Raizada

National Bureau of Fish Genetic
Resources, Canal Ring Road, Teli
Bagh, Lucknow – 226 002, UP,
India.

Akhilesh K. Yadav

Aquaculture Research Training
Unit, National Bureau of Fish
Genetic Resources, Chinhath,
Faizabad Road, Lucknow-227 105,
UP, India.

Prem P. Srivastava

National Bureau of Fish Genetic
Resources, Canal Ring Road, Teli
Bagh, Lucknow – 226 002, UP,
India.

Correspondence

Prem P. Srivastava

National Bureau of Fish Genetic
Resources, Canal Ring Road,
Teli Bagh, Lucknow – 226 002,
UP, India. (Present Address :
Fish Nutrition, Biochemistry
and Physiology Division, Central
Institute of Fisheries Education,
Panch Marg, Off Yari Road,
Mumbai, MS, India.)

Cellular changes in the gill of saul (*Channa striatus*) grow-out fed with various dietary fats

**Anita Bhatnagar, Rajesh Dayal, Shipra Chowdhary, Wazir S. Lakra, S. Raizada,
Akhilesh K. Yadav, Prem P. Srivastava**

ABSTRACT

Various fats were assessed for their impact on the gill of saul (*Channa striatus*). The grow-out (av. wt. 27.36±0.09 - 32.54±0.41g) were fed for 12-weeks with six diets and a control, F7 (NATFO). F1 (L3HUF) contains 0.5% n-3 fatty acid & 7.5% saturated oil; F2 (H3HUF) contains 1.0% n-3 fatty acid & 7.0% saturated oil; F3 (MUSOL) contains 8.0% mustard oil; F4 (LINOL) contains 8.0% linseed oil; F5 (MIXOL) contains 4.0% mustard oil and 4.0% linseed oil; F6 (SATOL) contains 8.0% saturated oil. The F-1, fed fishes showing knob-like swelling in primary gill lamella (PGL); F-2, showing swelling cartilaginous cells (CC); F-3, showing knob like swelling and cartilaginous cells; F-4, showing fusion of PGL, Secondary Gill Lamella (SGL) and CC; F-5, showing prominent CC and F-6, showing fusion of epithelial cells of PGL and SGL and CC. Gills of *C. striatus* fed with natural food showing normal PGL and SGL. It was summarized that addition of different fats had some impact in the gill structure (not useful in human food), however, cheaper fat source could be used for better growth and also to reduce the feed cost for aquaculture of this fish.

Keywords: *Channa striatus*, gills, histological alterations, dietary fats.

1. Introduction

The gill of the teleost apart from being the primary respiratory organ in fishes, and are also responsible for other important vital physiological functions like excretion of nitrogenous wastes, acid-base balance and ionic regulation. The primary function of the gill in fish is the osmotic regulation of water and salts at priority rather than the excretion of nitrogenous wastes. In freshwater fish, the gill must conserve salt and eliminate excess water. The histological changes in the gill tissue in fish on account of dietary supplementation are important markers for the assessment of the effects of dietary alterations. Histopathological changes have been widely used as biomarkers in the assessment of the fish health exposed to contaminants in lab [1,2] and field studies [3-5]. One of the main advantages of using histopathological markers in monitoring is that this category of biomarkers allows to study the target organs, including gills and liver that are responsible for important functions, such as excretion, deposition and bio-magnifications of xenobiotics in the fish [6]. The changes found in these organs are normally simpler to identify than functional ones [7], and serve as alarming signs of damages to general animal health [8]. Histopathological techniques are sensitive, rapid, comparatively inexpensive tools and reliable for the assessment of stress-response of dietary ingredients. So when fish are exposed to environmental pollutants, these vital functions are deleteriously affected and the functional impairment of gills can significantly damage the health of fish [9, 10, 12]. The gill surface is more than half of the entire body surface area. In fish, the internal environment is separated from the external environment only a few microns of delicate gill epithelium and thus the branchial function is very sensitive to environmental contamination. Gills have frequently been used in the assessment of impact of aquatic pollutants in marine as well as freshwater habitats [11]. Therefore, lesions in gill tissues can be the start of imbalance of the physiological and metabolic process of fish. Many investigators have reported the histopathological changes in the gills of different fish species exposed to pesticides [9, 13, 14].

A balanced feed and feeding in fish production system is necessary for the better production of healthy and quality fish. It is reported [14] that fish reared in intensive culture systems require all nutrients in a complete diet. The study to record the cellular changes in the fish gill on feeding any manipulative diet for a longer time is actually considered as an useful tool for the observation of its impact. Due to the regularly increasing fish demand, it is necessary to increase aquaculture production on dietary manipulations with increased dietary energy by adding rich fat contents and protein sources. Since the fish oil is not only costly but becoming less available, there is an urgent need to assess the dietary potential of various other available sources of fat from both animal and plant sources. In global scenario, the emphasis is being given to dietary replacement of animal fat with less expensive plant fat. In this connection, monitoring histological tissues of fish gill is the method to assess the impacts of various energy nutrient that we use as raw materials of plant and/or animal origin especially various types of fat contents.

Replacement of fish oil by vegetable oils has proved in many fishes without impacting on growth performances [15-18]. However, the impacts of various dietary oils on lipid metabolism of fish are still not very, particularly where fish oil provide the only source of highly unsaturated fatty acids, very much essential for catfishes. Variation in dietary oils may lead to imbalances in the essential or non-essential fatty acids, and may be differently affecting cellular architecture.

The objective of the present study was to compare the effect of different sources of dietary fats in practical diets of striped snakehead murrel fed on long-term basis on gill histology. The striped snakehead murrel, *Channa striatus* locally known as 'Saul', is one of the most important fish of Indian continent that has a great aquaculture potential. The commercial feeds have been reported to exhibit rich fat accumulations in the gill tissue of this fish which is a major concern to fish growers. However, the effect of dietary fats in order to provide higher dietary energy for better growth and improved health in this fish have not been evaluated, through evaluation of gill tissue and, therefore, was the main interest of present study.

2. Materials and Methods

Six type of feeds were formulated having similar feed ingredients in same quantities excepting different source of fat. Six diets (L3HUF, F1; H3HUF, F2; MUSOL, F3; LINOL, F4; MIXOL, F5; SATOL, F6) and a control (NATFO, F7) with natural food. F1, contains 0.5% n-3 fatty acid and 7.5% saturated oil; F2, contains 1.0% n-3 fatty acid and 7.0% saturated oil; F3, contains 8.0% mustard oil; F4, contains 8.0% linseed oil; F5, contains 4.0% mustard oil and 4% linseed oil; F6, contains 8% saturated oils. (Table 1). In order to evaluate the effect of different oil sources on the gill of *C. striatus*, the experiment was conducted in indoor condition in 14 (7 types of feed, 2 replicates) round plastic pools of 300 litre capacity, each filled-up with 100 litre borewell water. Each having two replications, stocked with 20 grow-out fish having an initial average weight 27.36 ± 0.09 g to 32.54 ± 0.41 g were plotted in each of the plastic pool after proper acclimatization. The pools were provided aeration from a portable aerator round the clock. During the experiment, the fishes were fed twice a day at 10:00 and 17:00 hours *ad libitum* per day. Rearing pools were cleaned every 2nd day and half of the water was replaced with fresh bore-well water to reduce the nitrogenous waste accumulated as debris and faecal matters.

After 12-weeks of feeding trials with seven feed combinations (Table-1) the animals were sacrificed. The gill tissue from control (F7, NATFO) and experimental fishes (feed with different fats (F1 to F6) were excised and fixed in 4 % formaldehyde and processed by standard histological techniques ie., kept in aqueous Bouin's fluid for 24-hr and washed for 8-hr in running tap water. The organs were routinely processed (dehydrated in ethanol series, embedded in paraffin, serially sectioned at 6 μ). Sections of the gill tissue were stained with Haematoxylin and Eosin (HE). Histological slides were observed under microscope (Labomed, Model: Digi 2) for assessment.

Table 1: Ingredients composition (w/w) of feeds for *Channa striatus*.

Feed Ingredients	F-1 (L3HUF)	F-2 (H3HUF)	F-3 (MUSOL)	F-4 (LINOL)	F-5 (MIXOL)	F-6 (SATOL)	F-7 (NATFO)
Soybean meal	41.0	41.0	41.0	41.0	41.0	41.0	-
Starch Soluble	25.0	25.0	25.0	25.0	25.0	25.0	-
Casein	20.0	20.0	20.0	20.0	20.0	20.0	-
Carboxy Methyl Cellulose	2.0	2.0	2.0	2.0	2.0	2.0	-
Papain	0.5	0.5	0.5	0.5	0.5	0.5	-
Vitamin & Mineral Mix.	3.5	3.5	3.5	3.5	3.5	3.5	-
Omega – 3 HUFA	0.5	1.0	-	-	-	-	-
Saturated Oil	7.5	7.0	-	-	-	8.0	-
Mustard Oil	-	-	8.0	-	4.0	-	-
Linseed Oil	-	-	-	8.0	4.0	-	-
Live Fish/ NATFO	-	-	-	-	-	-	100.0

L3HUF = Low Omega – 3 HUFA; H3HUF = High Omega – 3 HUFA; MUSOL = Mustard Oil; LINOL = Linseed Oil; MIXOL = Mixed Oil (Mustard Oil : Linseed Oil :: 1 : 1 w/w); SATOL = Saturated Oil; NATFO = Natural Food

3. Results and Discussion

3.1. Morphological Analyses of Gills

Figures 1 to 7 showed the gill arch of the *Channa striatus*, a gill arch is very peculiar to teleost fish. The following alterations were observed: hypertrophy, fusion of respiratory lamellae and destructuring of the primary and secondary gill lamellae.

Morphological alteration analyses in gills of *Channa striatus* collected after feeding fishes with different dietary fat showed that fishes were exhibiting nominal cellular alterations and there is no onset of pathological symptoms. This was confirmed by the fact that the impact indices for gill alterations within different feeding trials and the changes in gill tissue were more or less similar in most of the dietary fat. This condition indicated that the inclusion of dietary fat exerted a cellular modifications on the excretory system of this fish.

In the present study, the gills of *Channa striatus* in control group was shown a normal structure (Fig1) and gills of the lipid fed fishes showed some pathological changes at the end of the experimentation. The changes observed in the gill of *C. striatus* exposed to various dietary fat induced histological changes such as in F-1, fed fishes showing knob-like swelling in primary gill lamella (PGL) (Fig 2); F-2, showing swelling cartilaginous cells (CC) (Fig 3); F-3, showing knob like swelling and cartilaginous cells (Fig 4); F-4, showing fusion of PGL, Secondary Gill Lamella (SGL) and CC and dilation of primary and secondary gill lamellae, loss of architecture and severe disorganization were identified (Fig 5); F-5, showing prominent CC (Fig 6) and F-6, showing fusion of epithelial cells of PGL and SGL and CC. There is tendency of fusion of disorganized secondary gill filaments and tips became naked due to loss of epithelium (Fig 7). Gills of *C. striatus* fed with natural food showing normal PGL and SGL (Fig1).

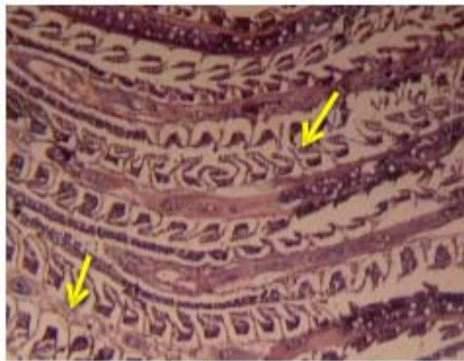


Fig 1: Gill of *C. striatus* fed with Natural feed (NATFO, F7) showing normal PGL, SGL (H/E 20X).

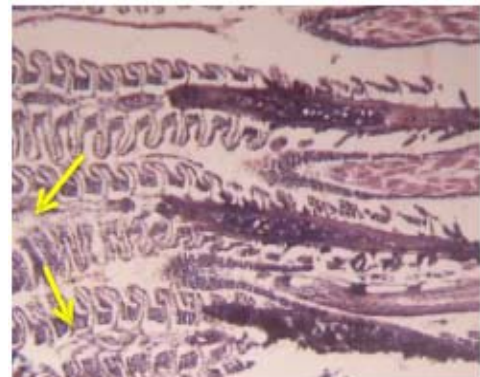

Fig 2: Gill of *C. striatus* fed with low unsaturated fatty acid (L3HUF) (F1) showing knob like swelling in PGL (H/E 20X).

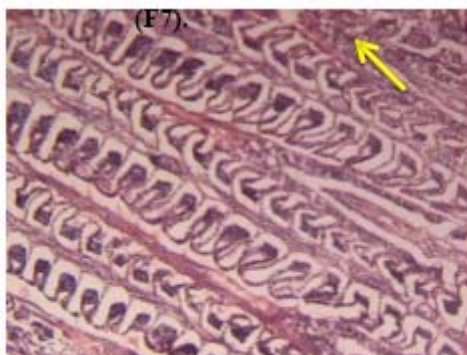


Fig 3: Gill of *C. striatus* fed with high unsaturated fatty acid (H3HUF) (F2) showing swollen cartilaginous cells (H/E 20X).

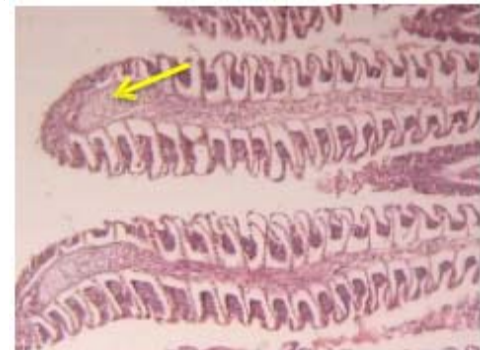


Fig 4: Gill of *C. striatus* fed fishes with F-3 (MUSOL) showing knob like swelling and cartilaginous cells (H/E 20X).

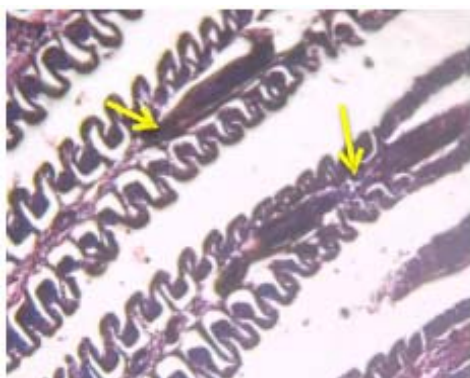


Fig 5: Gill of *C. striatus* fed with linseed oil (LINOL, F4) fusion of PGL and SGL and cartilaginous cells (H/E 20X).

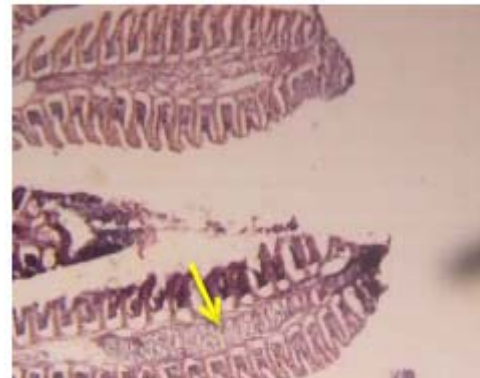

Fig 6: Gill of *C. striatus* fed with mixed oil (MIXOL, F5) showing prominent cartilaginous cells (H/E 20X).

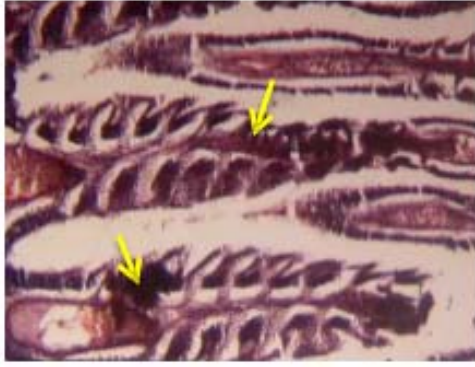


Fig 7: Gill of *C. striatus* fed with saturated oil (SATOL, F6) F-6, fusion of epithelial cells of PGL and SGL and cartilaginous cells (H/E 20X).

It has been reported that the dietary stress caused by the variations in the fats quality and pathological agents induced the proliferation of mucous cells and increased secretion [19, 20]. The huge quantity of mucus secretion acts as a defense mechanism against several substances [21]. The most frequently observed changes when the *C. striatus* gill curved secondary lamellae, lamellar necrosis and ballooning gill filament. These findings are in reliable with the works of [22] on *C. carpio* and *O. mossambicus* exposed to different concentrations of karate and curacron. The histopathological alterations of gill can result in respiratory failure problems with acid-base balance imbalances [23]. Hyperplasia with lamellar fusion, epithelial hypertrophy with epithelial separation from basement membranes and general necrosis have reported following exposure to DDT and malathion [24] and exposure to Paraquat dichloride [25]. Similarly, Cengiz [26] observed histopathological effect of deltamethrin on the gill of common carp. Tilak [27] reported that chlorpyrifos intoxication in fish, *Catla catla* caused dropsy, vascular degeneration, cloudy swelling, necrosis and other degenerative changes in epithelial and pillar cells of the gills. Club shaped lamellae are an example of progressive degeneration in the gills. In the present study, the epithelial hyperplasia could be a consequence of the epithelial detachment [28] and lamellar fusion could be a result of both hyperplasia of epithelial cells [29]. Vacuolization and ballooning of secondary lamellae were predominant and this might be due to inflammation brought about by pesticide toxicity. Similar results were reported earlier by various authors [22]. Roy and Munshi [30] have showed that fusion of bases of secondary gill filaments was a mechanism adopted by the fish to increase the respiratory area was affected by the pesticide toxicity. This findings on histological alterations in gills was in concordance with the present study.

5. Conclusion

In conclusion, the histological changes observed in the gills of *C. striatus* indicate that the fish were responding to the direct effect of the dietary lipids/ fat. Hence safety measures must be taken into account when fat is being used in fish through dietary manipulations. It was finally concluded that out of six types of fats used in the present study, the essential fatty acid (H3HUF, F2) is considered best as a feed substitute in the artificial diets. The other fats have shown very mild to moderate level of changes in the gill tissue at 8% addition in the diet in a 12-week trial. Therefore, these fatty acids may be used in combination with other fats to cut down the feed price

without effecting the survival and growth of *C. striatus*. The observations, in the present study, suggest that manipulation with different fat sources in the feed has direct relation with cellular level modifications in the gills of *Channa striatus*.

6. Acknowledgements

Authors are very grateful to the Director, NBFGR, Lucknow for providing facilities to conduct this research work.

7. References

1. Wester PW. & J. H. Canton. The usefulness of histopathology in aquatic toxicity studies. *Comparative Biochemistry and Physiology (C)* 1991; 100: 115-117.
2. Thophon S, Kruatrachue M, Upathan E S, Pokethitiyook P, Sahaphong S, Jarikhuan S. Histopathological alterations of white seabass, *Lates calcarifer* in acute and subchronic cadmium exposure. *Environmental Pollution* 2003; 121:307-320.
3. Hinton DE, P. C. Baumann, G. R. Gardner, W. E. Hawkins JD, Hendricks RA, Murchelano & MS. Okihiro. Histopathologic biomarkers. In: Hugget, R., R. Kimerle, P. Mehrle & H. Bergman (Eds.). *Biomarkers – biochemical, physiological and histological markers of anthropogenic stress*. Boca Raton, Lewis Publishers, 1992; 155-195.
4. Schwaiger J, Wanke R, Adam S, Pawert M, Honnen W, Triebkorn R. The use of histopathological indicators to evaluate contaminant-related stress in fish. *Journal of Aquatic Ecosystem Stress and Recovery* 1997; 6:75-86.
5. Teh SJ, Adams SM, Hinton DE. Histopathological biomarkers in feral freshwater fish populations exposed to different types of contaminant stress. *Aquatic Toxicology* 1997; 37:51-70.
6. Gernhofer M, Pawet M, Schramm M, Müller E, Triebkorn R. Ultrastructural biomarkers as tools to characterize the health status of fish in contaminated streams. *Journal of Aquatic Ecosystem Stress and Recovery* 2001; 8:241-260.
7. Fanta E, Rios FS, Romão S, Vianna ACC, Freiburger S. Histopathology of fish *Corydoras paleatus* contaminated with sublethal levels of organophosphorus in water and food. *Ecotoxicology and Environmental Safety* 2003; 54: 119-130.
8. Hinton DE, Laurén DJ. Liver structural alterations accompanying chronic toxicity in fishes potential biomarkers of exposure. Pp. 51-65. In: McCarthy, J.F. & L.R. Shugart (Eds.). 1990. *Biomarkers of Environmental Contamination*. Boca Raton, Lewis Publishers.
9. Alazemi BM, Lewis JW, Andrews EB. Gill damage in the freshwater fish *Gnathonemus petersii* (Family: Mormyridae) exposed to selected pollutants an ultra-structural study. *Environ Technol* 1996; 17:225-238.
10. Athikesavan S, Vincent S, Ambrose T, Velmurugan B. Nickel induced histopathological changes in the different tissues of freshwater fish *Hypophthalmichthys molitrix* (Valenciennes). *J Environ Biol* 2006; 27:391-395.
11. Erkmén B, Caliskan M, Yerli SV. Histopathological effects of cyphenothrin on the gills of the *Lebistes reticulatus*. *Vet Hum Toxicol* 2000; 42:71-78.
12. Kumar S, Tembhe M. *Fish and Fisheries*. New Central agencies (P) Ltd., London, 2010.
13. Radhakrishnan NC. *Studies on pesticide-induced changes in chosen fishes*. Ph. D. Thesis, Manonmaniam Sundaranar University, Tirunelveli, India, 2002.

14. Riche M, Garling D. North Central Regional Aquaculture Centre and United State Department of Agriculture USDA, 2003; 1-4.
15. Caballero MJ, Obach A, Rosenlund G, Montero D, Gisvold M, Izquierdo. MS Aquaculture 2002; 214:253-271.
16. Bell JG, McGhee F, Campbell PJ, Sargent JR. Aquaculture 2003; 218: 515-528.
17. Izquierdo MS, Obach A, Arantzamendi L, Montero D, Robaina L, Rosenlund G. Aquaculture Nutrition 2003, 9: 397-407.
18. Regost C, Arzel J, Robien J, Rosenlund G, Kaushik SJ. Total replacement of fish oil by soybean or linseed oil with a return to fish oil in turbot (*Psetta maxima*) - 1. Growth performance flesh fatty acid profile and lipid metabolism. Aquaculture 2003; 217:465-482.
19. Cardoso EL, Chiarini-Gracia H, Ferreira RMA, Poli CR. Morphological changes in the gills of *Lophiosilurus alexandri* exposed to unionized ammonia. J Fish Biol 1996; 49:778-787.
20. Richmonds C, Dutta HM. Histopathological changes induced by malathion in the gills of bluegill *Lepomis macrochirus*. Bull Environ Contam Toxicol 1989; 43:123-130.
21. Mazon AF, Cerqueira CCC, Monteiro EAS, Fernandes MN. Acute copper exposure in freshwater fish Morphological and physiological effects. In Val AL Almeida-Val VMF, (Eds.), Biology of Tropical Fishes, INPA, Manaus, 1999; 263-275.
22. Radhakrishnan NC. Studies on pesticide-induced changes in chosen fishes. Ph. D. Thesis, Manonmaniam Sundaranar University, Tirunelveli, India, 2002.
23. Alazemi BM, Lewis JW, Andrews EB. Gill damage in the freshwater fish *Gnathonemus petersii* (Family: Mormyridae) exposed to selected pollutants: an ultra-structural study. Environ Technol 1996; 17:225-238.
24. Walsh AH, Ribelin WE. The pathology of pesticide poisoning In: Gopalakrishnan KS, 1990: Studies on the effects of some pesticides on the fish *Etroplus maculatus* (Bloch), Ph. D Thesis, Cochin University of Science and Technology, Kerala, India, 1975; 124-125.
25. Hendricks JD. Effects of various herbicides on histology of yearling *Coho salmon*, Appendix II In: Gopalakrishnan KS, 1990: Studies on the effects of some pesticides on the fish *Etroplus maculatus* (Bloch), Ph. D Thesis, Cochin University of Science and Technology, Kerala, India, 1979.
26. Cengiz EI. Gill and kidney histopathology in the freshwater fish *Cyprinus carpio* after acute exposure to deltamethrin. Environmental Toxicology and Pharmacology 2006; 22:200-204.
27. Tilak KS, Koteswara RD, Veeraiah K. Effects of chlorpyrifos on histopathology of fish *Catla catla*. J Ecotoxicol Environ Monitor 2005; 15(2):127-140.
28. Machado M, Fanta E. Effects of the organophorous methyl parathion on the branchial epithelium of a freshwater fish *Metynnis roosevelti*. Braz Arch Boil Techn 2003; 46(3):361-372.
29. Morrison R, Nowak B, Carson J. The histopathological effects of a levamisole adjuvanted *Vibrio anguillarum* vaccine on Atlantic salmon (*Salmo salar* L.). Aquaculture 2001; 195:23-33.
30. Roy PK, Munshi JSD. Malathion induced structural and morphometric changes of gills of a freshwater major carp, *Cirrhinus mrigala* (Harr.). J Environ Biol 1991; 12(1):79-87.